

Clinical anatomy of cervical spondylosis

Pablo González-Uriel¹, V. Armesto Pérez², Juan A. Suárez-Quintanilla³

¹Clinical Neurophysiology Unit, Lucus Augusti University Hospital, 27003 Lugo, Spain

²Radiology Unit, Lucus Augusti University Hospital, 27003 Lugo, Spain

³Section of Human Anatomy, Department of Morphological Sciences, Faculty of Medicine, University of Santiago de Compostela, 15782 Spain

SUMMARY

The aim of this study is to describe the anatomical alterations in complementary tests (MRI and EMG) in patients with cervicobrachialgia according to sex and age. Retrospective study of 184 patients with cervicobrachialgia who underwent cervical MRI and EMG. The variables analyzed were gender, age, elements of spondylosis (osteophytes, arthropathy, spondylolisthesis and canal stenosis), the type of disc disease (protrusion and herniated disc) and curvature in the sagittal plane. The EMG was used to evaluate the neurogenic findings in the muscles dependent on the spinal roots of C4 to C8-T1.

Average age was 53.65 ± 11.96 years. The patients were evaluated for the presence of osteophytes (n = 111), arthropathy (n = 76), spondylolisthesis (n = 15) and stenosis of the spinal canal (n = 35). The highest incidences were osteophytes in C5-C6 (n=108), protrusions in C5-C6 (n=58), herniated disc in C5-C6 (n=18) and neurogenic findings in C7 (n=130). The rectification of cervical lordosis appeared in 124 patients.

Spondylosis increases with age. Disc herniations, disc protrusions and motor radiculopathy are more frequent in the 5th to 6th years of life. In patients with cervicobrachialgia, the sagittal rectification is more common than the normal lordosis.

Key words: Cervicobrachialgia – Spondylosis – Discopathy – Radiculopathy – Cervical MRI – EMG

INTRODUCTION

Cervicalgia and cervicobrachialgia are two clinical syndromes characterized by the presence of cervical pain with or without irradiation towards the arm. They have various causes, the most frequent being degenerative and traumatic.

Cervicalgia is a clinical symptom characterized by pain in the cervical region that may extend towards the head, shoulders and upper limb. It can be accompanied by functional impotence for flexion-extension, rotation and/or lateralization movements. Cervicalgia often appears spontaneously (Devereaux, 2009), without any clear acute onset. In addition to radiculopathy (RAD) and cervical myelopathy, it constitutes one of the most common clinical syndromes affecting the cervical spine. Its prevalence rate is almost 20% of the population aged 40 or over in developed countries (Grob et al., 2007). Cervicalgia may be the outcome of mechanical disorders due to spondylosis with or without previous trauma, or due to cancer, and inflammatory or infectious diseases (Iyer and Kim, 2016).

Cervicobrachialgia is characterized by the presence of pain associated or not with sensory and/or motor deficit, in a dermatome and/or concrete myotome of a cervical nerve root, with involvement from the neck along the innervated territory by the

Corresponding author: Dr. Juan Antonio Suárez Quintanilla.
Section of Human Anatomy, Department of Morphological Sciences, Faculty of Medicine, University of Santiago de Compostela, San Francisco Street s/n, 15782 Santiago of Compostela, Spain.

E-mail: juanantonisuarez.suarez@usc.es

Submitted: 4 May 2020. Accepted: 12 May 2020.

injured root. It is caused by radiculopathy. A study of Radhakrishnan et al. (1994) revealed that the most affected root was C7, followed by C6.

Cervical radiculopathy is a lesion of a cervical nerve root, mostly by compression or irritation of the fibers or the dorsal spinal ganglion in the context of spondylosis (Fig. 1), with or without disc herniation associated (Fouyas et al., 2002; Carette and Fehlings, 2005). Its physiopathological base is inflammation, with elevated cytokines and other markers found in biopsies and serum (Stafford et al., 2007; Patel and Perloff, 2018). The presentation of RAD varies according to the affected nerve root, with pain and/or a burning sensation in the neck, shoulder and/or arm, muscle weakness, sensory disorders such as paresthesia, dysesthesia and hypoesthesia, and alteration of deep tendon reflexes, alone or in combination (Roh et al., 2005). However, cervichalgia without irradiating to the arm does not exclude the presence of RAD.

The most frequent etiology of radiculopathy is spondylosis. It refers to nonspecific and degenerative changes in any region of the spine, that can cause cervical pain and repercussions on the degrees of neck mobility [3]. The spondylosis elements are more prevalent in the lumbar than in the cervical segment [3]. Its pathophysiology is not completely known, but it is intuited that it consists of a process of progressive degeneration of the intervertebral discs (loss of water and elasticity) and of the joint facets, which is going to be associated with a bone reaction with the formation of osteophytes and arthritic deformation and in the architecture of the vertebral bodies, hypertrophy of the longitudinal ligaments and the yellow ligament (Manifold and McCann, 1999). Among its consequences is intervertebral foraminal stenosis, which can cause compression of the nerve root and root symptoms with cervicobrachialgia (Lestini and Wiesel, 1989).

In addition, the presence of elements of spondylosis and discopathy can affect the vertebral alignment (Harrison et al., 2001), while the misalignment, by incorrect postures, can make an unequal distribution of loads and promote disc degeneration.

There are no universally accepted criteria for diagnosing RAD (Wainner and Gill, 2000; Rao, 2002), which relies on the patient's medical history, physical examination, and other additional tests such as MRI or electrodiagnosis (EDX). The first test of choice for suspected RAD is MRI (Brown et al., 1988; Mink et al., 2003; Yoon, 2011), given that it enables the imaging of soft tissue. Since the 1940s, with the report of Hoefer and Guttman in 1944, EDX has been shown to be useful for diagnosing motor radiculopathies, helping to determine the anatomical level, severity and chronicity (Carette and Fehlings, 2005).

The medical histories and diagnostic tests, MRI and electromyography (EMG) of 184 patients with

cervicobrachialgia were reviewed in order to analyze the physiopathology underlying the symptoms.

The objectives of this study were two. First, use MRI to describe the appearance of discopathy (DIS), spondylosis elements and sagittal curvature in patients with cervicobrachialgia, and their relationship with gender and age. And second, use the EDX to determine the level and, presumably, the anatomical location of the root motor neurological injury and its relationship to gender and age.

MATERIALS AND METHODS

This is a retrospective study of 184 patients with cervicobrachialgia who, on the clinical suspicion of cervical radiculopathy, underwent cervical MRI and EMG during the period between August 2016 and August 2018. The medical histories and the above-mentioned diagnostic tests were reviewed. The study was approved by the Hospital Ethics Committee.

Inclusion criteria: patients aged 18 years or over with cervicobrachialgia and clinically suspected cervical RAD attending the University Hospital Lucus Augusti (Lugo, Northwestern Spain), who had initially undergone examination by a consultant from the departments of traumatology, rehabilitation, neurosurgery, and/or neurology, and later electromyographer. Patients who had undergone MRI in high-field superconducting magnet (1.5 T) Siemens Symphony, Ge Signa HDxt and Signa Excite with Quantum gradients. Patients who had undergone EMG with concentric needle electrodes

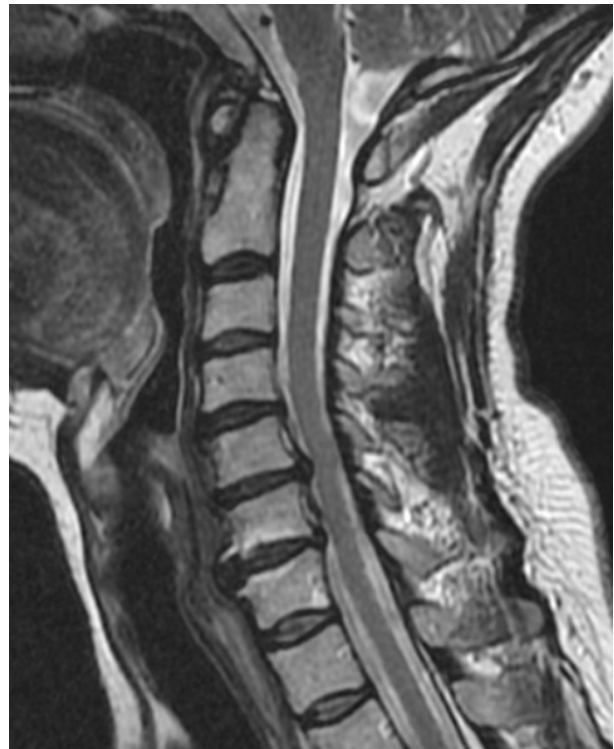

Fig 1. Sagittal section of the cervical spine in T2 MRI. Herniated disc C5-C6. Disc protrusion C6-C7.

using a DANTEC KEYPOINT® system one month after the onset of symptoms. The time lapse between both tests did not exceed three months.

Exclusion criteria: patients under 18 years. Underlying neurological disease: myelopathy, motor neuronopathy, plexopathies, polyneuropathies, disorders of the neuromuscular union, and myopathies (excluding those with EDX). Arnold-Chiari syndrome and syringomyelia. Seronegative spondyloarthropathy: ankylosing spondylitis, and spondyloarthropathy secondary to inflammatory bowel disease, psoriatic and reactive arthritis. Scoliosis with a Cobb angle greater than 20°. Cervical hyperlordosis diagnosed with MRI. Pathological dorsal kyphosis. Congenital vertebral stenosis. Cervical spine surgery (all types), vertebral fractures, and vertebral tumors. Infections such as osteomyelitis, discitis, and spinal tuberculosis.

A descriptive statistical analysis of measures of the central tendency and dispersion of quantitative variables, and the proportions of qualitative variables was done. The cut-off of statistical significance was an alpha of $p < 0.05$. Statistical analysis was performed using the software IBM SPSS Statistics 22.0.

The following variables were analyzed: gender and age (which was categorized into three groups).

The MRI evaluated the presence or absence of elements of spondylosis (osteophytes, arthropathy, listhesis, and canal stenosis), the osteophytes were described in every cervical levels from C3-C4 to C7-T1; the number of spaces with disc pathology, and the type of disc pathology (protrusion or herniated disc); and curvature on the sagittal plane (rectification or cervical lordosis).

The analysis and classification of disc pathology was in accordance with the recommendations regarding nomenclature of the North American Spine, American Society of Spine Radiology, and the American Society of Neuroradiology (Fardon et al., 2014). Protrusion (PROT) was defined as a subtype of hernia characterized by a maximum diameter of the displaced disc fragment smaller than the disc measured on the same plane. Protrusion could be either focal, when it affects at least 25% of disc circumference (or less than 90°), or broad based, when it affects 25-50% of the disc circumference. Herniated disc (HD) was defined as localized disc displacement beyond the limits of disc space (Perez et al., 2012), and four degrees had been established: protrusion, extrusion, migration and sequestered. In this study, the variable hernia referred to extrusion, migration, and sequestration of disc fragments (Fig. 1).

The cervical MRI on the sagittal and axial planes were analyzed and the T1 and T2 sequences were enhanced by gradient echo sequencing, according to the recommendations of Vertinsky et al. (2007).

The EMG concentric needle electrodes were used in a DANTEC KEYPOINT® system to evalu-

ate the presence of acute or chronic motor neurogenic findings (mild, moderate, or severe) in muscles dependent on the spinal roots from C4 to C8-T1. They were classified as: motor neurogenic absence in the myotome, or mild, moderate, and severe motor neurogens findings. The EDX and the RAD classification were in line with the recommendations of the American Association of Electrodiagnostic Medicine (1999). Nerve conduction studies (ENG) and concentric needle EMG were performed on upper limbs (Table 1). ENG were used to explore at least one motor nerve and one sensory nerve, in order to exclude compressive mononeuropathies and/or polyneuropathy. EMG was used to evaluate the presence of signs of acute denervation (fibrillations and positive waves), and potential motor unit denervation (MUAPs), chronic neurogens (with an amplitude equal to or greater than 5 mV, and longer than 16 ms in duration). The presence of reinnervating polyphasic MUAPs was not evaluated. The following muscles were evaluated as a guide of each cervical root (a minimum of 6 muscles) (Dillingham et al., 2001) (Table 1)

Table 1. Muscles explored in each myotome

Root	Muscles explored
Root C4	Trapezius
Root C5	Deltoid, Supraspinatus
Root C6	Brachial biceps
Root C7	Brachial triceps, common extensor of the fingers
Root C8-T1	Common extensor of the fingers, first dorsal interosseous muscle.

Also, paraspinal muscles but they were not used to locate the affected level.

RESULTS

Characteristics of the sample

Diagnostic tests (MRI and EMG) of 184 patients were analyzed: 125 women (67.9%), and 59 men (32.1%); mean age was 53.65 years, standard deviation (SD) 11.96 years, with a minimum age of 25 years and a maximum age of 84 years. Three age cohorts were established: 45 years or under (AG1), 58 patients (31.5%); 46 to 60 years (AG2), 90 patients (48.9%); and over 61 years (AG3), 36 patients (19.6%).

Discopathy: protrusion (PROT) and herniated disc (HD)

The distribution in the number of DIS (the sum of PROT and HD) per spine according to gender and AG was as follows (Table 2)

The distribution of the disc protrusions according to gender is shown in Table 3. The level with the highest percentage of PROT was C5-C6, with 31.7% ($n = 58$), followed by C6-C7 ($n = 41$), with

Table 2. Number of discopathies according to age and gender

DIS	TOTAL	MEN	WOMEN
AG1	1.09 ± 1,09	1.00 ± 0,86	1.09 ± 1,09
AG2	1.39 ± 1,26	1.97 ± 1,29	1.39 ± 1,26
AG3	1.14 ± 1,15	1.00 ± 0,92	1.14 ± 1,15
Total	1.23 ± 1,19	1.56 ± 1,22	1.10 ± 1,16

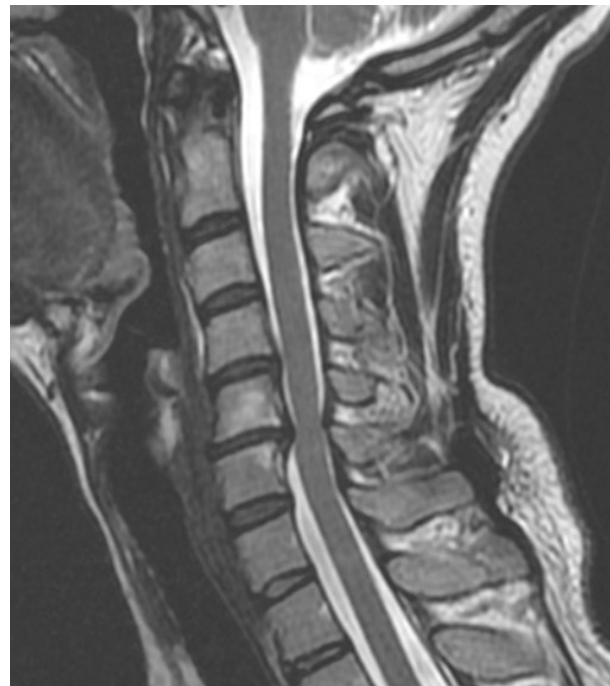22.4%. The level with the lowest percentage was C7-T1 with 3.8% (n = 7). Only disc protrusion at level C3-C4, which is more prevalent in males, has had statistical significance (p = 0.014).

The distribution of the disc protrusions according to the age group did not present statistical significance in any of the anatomical levels, from C3-C4 to C7-C8. In any case, disc protrusions were always more prevalent in AG2, for all the intervertebral levels studied, as shown in Table 3.

The distribution of herniated disc according to gender is shown in Table 4. The level with the highest percentage of HD was C5-C6, with 9.8% followed by C6-C7, with 8.7%. The level with the lowest percentage of HD was C7-T1, with 1.1%. Only the herniated disc at level C3-C4, which was more prevalent in males, had statistical significance (p = 0.014).

The distribution of herniated discs according to the age group did not present statistical significance in any of the anatomical levels, from C3-C4 to C7-C8. In any case, the disc protrusions were always slightly more prevalent in the AG2, for all the intervertebral levels studied, in a similar way to what happened with the disc protrusions, as shown in Table 4.

Discopathy (the sum of PROT and HD) did present with statistically significant association at the C3-C4 level, with channel stenosis (p = 0.005) and with gender (p = 0.004); at level C5-C6, with the

**Fig 2.** Sagittal section of the cervical spine in T2 MRI. Rectification. Spondylolisthesis C6-C7. Canal stenosis.

concomitant presence of DIS at C6-C7 (p = 0.006) and with correction of lordosis (p = 0.047). Finally, at level C6-C7, with the coexistence of DIS C7-T1 (p = 0.006).

Elements of spondylosis

MRI was used to evaluate the presence of osteophytes (DC), which were positive in 60.3% of patients (n=111); arthropathy, which was positive in 41.3% of patients (n= 76); spondylolisthesis, which was positive in 8.2% (n=15), and spinal canal stenosis, which was positive in 19.0% of patients (n=35) (Fig. 2).

The number of intervertebral cervical levels with osteophytes per spine was 1.26±1.27 (mean±SD) (Table 5). The distribution of the number of osteo-

Table 3. Number of disc protrusion according to gender and age group

PROT	+	%	MALE (59)	FEMALE (125)	p	AG 1 (58)	AG 2 (90)	AG 3 (36)	p
C3 - C4	19	10.33	10	9	0.014	4	9	6	0.536
C4 - C5	34	18.48	13	21	0.694	9	19	6	0.781
C5 - C6	58	31.52	21	37	0.682	20	29	9	0.473
C6 - C7	41	22.28	12	29	0.832	11	23	7	0.774
C7 - T1	7	3.80	4	3	0.223	1	4	2	0.520

Table 4. Number of herniated discs according to gender and age group

HD	+	%	MALE (59)	FEMALE (125)	p	AG 1 (58)	AG 2 (90)	AG 3 (36)	p
C3 - C4	10	5.43	6	4	0.014	2	6	2	0.536
C4 - C5	10	5.43	3	7	0.694	3	6	1	0.781
C5 - C6	18	9.78	6	12	0.682	8	8	2	0.473
C6 - C7	16	8.70	6	10	0.832	4	9	3	0.774
C7 - T1	2	1.08	0	2	0.223	0	2	0	0.520

Table 5. Number of DC according to gender and age group

DC	TOTAL	MALE	FEMALE
AG1	0.48±0.86	0.82 ±1.07	0.34±0.72
AG2	1.40±1.15	1.32 ±1.19	1.45±1.14
AG3	2.14±1.41	2.00 ±1.06	2.18±1.51
TOTAL	1.26±1.27	1.27 ±1.18	1.25±1.31

phytes per spine in the sample according to AG and gender was as follows:

The highest means were for AG3 in both men and women. The presence or not of osteophytes in the intervertebral spaces was evaluated and it was greater in the intervertebral space C5-C6, accounting for 58.5% (n=108), followed by the intervertebral space C6-C7, with a 51.1%, (n=94). The space with the fewest osteophytes was C7-T1 accounting for 15.2% (n=28).

The frequency of appearance of the spondylosis elements according to gender has not been statistically significant for any of the variables studied, as is shown in Table 6.

The frequency of appearance of the spondylosis elements, according to the age group, is shown in Table 6. Osteophytes (p=0.000), arthropathy (p=0.000) and spinal canal stenosis (p=0.000) have shown a statistically significant correlation with aging, being the most prevalent variables in the AG 3.

A statistically significant correlation was found between the presence of osteophytes and age (p=0.000), and the other elements of spondylosis: arthropathy (p=0.000), spondylolisthesis (p=0.030), and canal stenosis (p=0.008). A similar tendency was observed with arthropathy, with a strong correlation with canal stenosis (p=0.000), spondylolisthesis (p=0.009), and age (p=0.000). In contrast, spondylolisthesis was neither correlated to age (p=0.097), nor spinal canal stenosis (p=0.431).

Curvatures on the sagittal plane

The presence of rectification of the physiological cervical lordosis was assessed by means of MRI in supine decubitus, which was positive in 67.4% of the patients (n=124), while 32.6% of the columns presented the cervical lordotic curvature preserved (n=60). The presence of rectification has not been associated with gender (male: 38/59; female: 86/125; p=0.553) or age (AG1: 40/58; AG2: 61/90; AG3: 23/36; p=0.873).

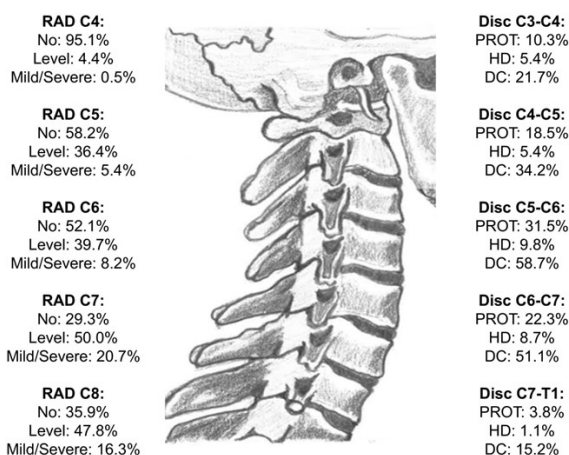


Fig 3. Sagittal illustration of the cervical spine. EMG neurogenic findings in every nerve root. Discopathy and DC.

The loss of curvature had a statistically significant association with the presence of osteophytes (p=0.046), osteophytes in C5-C6 intervertebral level (p=0.009), with DIS C5-C6 (p=0.047), and with C6 motor radiculopathy (p=0.002).

EMG neurogenic findings

The root with most motor neurogenics findings was C7, with 70.5% of the examinations revealing disorders (n=130), followed by C8, with 64.1% (n=118). The root with the fewest acute or chronic motor neurogenics findings was C4, with 95.1% of normal examinations (n=9) (Fig. 3).

A statistically significant correlation was found between C7 RAD and gender in men (m=49/59; w=81/125; p=0.011). The frequency of C5 RAD increased with age, being highest in AG3 (AG1=22/58; AG2=33/90; AG3=22/36; p=0.033); however, the remaining roots presented a similar behaviour to discopathies, with the highest incidence in AG2 (45-60 years).

As for the elements of spondylosis, a relationship was observed between root C8 and osteophytes in C7-T1 intervertebral level (p=0.010) and with osteophytes in C5-C6 (p=0.035); arthropathy was related to the appearance of RAD C5 (p=0.029), C6 (p=0.046), and C8 (p=0.004); no correlation was found between spondylolisthesis, but a correlation was observed with spinal canal stenosis, in root C5 (p=0.016) and C8 (p=0.030). A statistically significant correlation was found between osteophytes in C5-C6 and in C4-C5 (52/184; p=0.000); osteophytes in C6-C7 (76/184; p=0.000); osteo-

Table 6. Spondylosis elements according to gender and age group

N=184	+	%	MALE (59)	FEMALE (125)	p	AG 1 (58)	AG 2 (90)	AG 3 (36)	p
OSTEOPHYTES	111	60.33%	38	73	0.432	17	64	30	0.000
ARTHROPATHY	76	41.3%	27	49	0.399	7	40	29	0.000
SPONDYLOLISTESIS	15	8.15%	5	10	0.913	1	10	4	0.097
SPINAL CANAL STENOSIS	35	19.02%	16	19	0.055	2	18	15	0.000

phytes in C7-T1 (25/184; $p=0.000$); arthropathy ($p=0.000$); listhesis ($p=0.004$); spinal canal stenosis ($p=0.004$); C5-C6 discopathy ($p=0.000$); and C6 RAD ($p=0.003$).

No correlation was found between C4-C5 DIS and C5 RAD, neither in the presence nor absence of osteophytes in C4-C5 (absence $p=0.986$; presence $p=0.905$). No correlation was found between la C5-C6 DIS and C6 RAD, neither in the presence nor absence of osteophytes in C5-C6 (absence $p=0.212$; presence $p=0.776$). No correlation was observed between la C6-C7 DIS and C7 RAD, neither in the presence nor absence of osteophytes in C6-C7 (absence $p=0.639$; presence $p=0.633$). No relation was found between C7-T1 DIS and C8-T1 RAD, neither in the presence nor absence of osteophytes in C7-T1 (absence $p=0.106$; presence $p=0.678$).

DISCUSSION

There have been no differences between genders in terms of discopathies, spondylosis elements or radiculopathies. On the other hand, there have been differences in terms of age. Discopathy and radiculopathy have been more prevalent in AG2, while spondylosis elements, mainly osteophytes, have been more prevalent in AG3.

In our sample we found a greater amount of osteophytes in the C5-C6 space (58.7%), in the same way as in previous reviews by Harrison et al. (2001) and Ezra et al. (2019) with studies on corpses. Second in frequency was space C6-C7 (51.1%), as well as the studies by Weber et al. (2003) and Kim et al. (2012). Harrison et al. (2001), and Ezra et al. (2019), postulate that the highest frequency in the C5-C6 space (and with larger osteophytes) coincides with the cervical lordotic peak, which is located at C5, exposing the C5-C6 disc to the maximum of flexion and extension movements. It is assumed that the etiology of the osteophytes is age dependent ($p = 0.000$) and is related to disc degeneration and the presence of previous trauma. As data supporting the latter, in our series 9 patients younger than 45 years who presented as the only finding osteophytes in C5-C6 level had previously suffered a traffic accident. Moreover, similar to the studies of Nathan (1962), and Ezra et al. (2019), in our series the percentage of patients with osteophytes was greater in men (64.4%) than in women (58.4%), but the correlation was not statistically significant ($m=38/59$; $w=73/125$; $p=0.437$). Osteophytes appear and increase with age, as well as arthropathy and canal stenosis. However, none of the variables of spondylosis were significantly associated to gender.

The DIS, PROT and HD, apart from the degenerative findings of the disc, with loss of height, density and elasticity, has not presented a statistically significant association with gender or with age. However, for both entities, a greater frequency has

been seen in AG2, which is related to the natural history of these injuries. It is known that both the symptoms and the material herniated to the spinal canal, in most patients, decrease after a few months (Postacchini, 2001). For the lumbar region, Adams et al. (2015), argue that some discs degenerate and others do not, because they are subjected to an excessive mechanical load. This principle could be applied to the cervical spine, and more specifically, to the intervertebral disc C5-C6, which is the place where the lordotic curve is inverted, and is subject to greater mechanical stress.

Whereas the incidence of these lesions peaks at the age of 50, spondylosis is most prevalent from the age of 60 onwards (Heller, 1992). According with the early study of Hadley (1957), the uncovertebral joints of the cervical spine sustain axial loads, and reduce stress on the intervertebral disc; thus, the frequency of PROT or HD is lower than in the lumbar region.

For the evaluation of the vertebral alignment in the sagittal plane in our patients with cervicobrachialgia, 32.8% of the spines preserved the cervical lordotic curvature ($n = 60$), while 67.2% showed a loss of the physiological curvature ($n = 124$). In our series, the loss of curvature was significantly correlated with the presence of osteophytes ($p = 0.046$), osteophytes in C5-C6 spinal level ($p = 0.009$), DIS C5-C6 ($p = 0.047$) and RAD motor C6 ($p = 0.002$). However, the type of sagittal vertebral alignment has not had a statistically significant correlation with gender ($p=0.553$) or with age ($p=0.873$).

It has been widely assumed that the normal alignment of the cervical vertebrae in the sagittal plane is a lordotic curve. However, the studies of Takeshima et al. (2002) and Hey et al. (2016) have reported patients without cervical pathology who present correction of physiological lordosis. The type of cervical vertebral alignment can be considered as an adaptation to correct changes in the thoracic and lumbar regions in order to balance the head in the pelvis to preserve horizontal vision (Scheer et al., 2013). In 2009, the prospective study by Okada et al. (2009) on cervical vertebral alignment showed that the loss of lordosis was related to progressive degenerative changes in patients with preserved lordosis, but not with a higher incidence of clinical events.

The present study has several limitations in this way. First, the study was based on the findings of cervical MRI in the supine position. Second, complete x-rays of the spine were not performed vertically; therefore, the thoracic and lumbar regions were not evaluated. Third, the results were categorized in terms of the presence or absence of cervical rectification, labelling the spines with kyphosis in the spinal rectification group, as Chiba et al. (2006) in the prospective study about laminoplasty for cervical myelopathy. Bearing in mind the above limitations, the highest prevalence of the loss of

lordosis in patients with cervicobrachialgia are in line with the view of Hey et al. (2017). Hence, in accordance with McAviney et al. (2005), it is plausible to believe that one of the causes for the loss of curvature is to maintain postures against pain, as occurs in patients suffering from temporomandibular joint disorders (Bendilayi et al., 2018).

In our series of 184 patients the root with the most neurogenic findings was C7, which coincides with the work of Radhakrishnan et al. (1994). However, in our series, the second most frequent RAD engine was the root C8-T1, and the third was the root C6, while in the study by Radhakrishnan et al. (1994), the third was our second root with the highest frequency. Noteworthy is the large number of chronic neurogenic findings found in the muscles dependent on C8-T1, compared to the small proportion of DIS and osteophytes at the C7-T1 level, without foraminal stenosis. This finding was previously reported in the retrospective study by Hehir et al. (2012) of patients with C8 RAD, and was attributed to a probable lesion in the C7 root in a prefixed brachial plexus, previously described by Lee et al. (1992) and Uysal et al. (2003). It has been conjectured that spinal compression can lead to vascular lesions with degeneration of the anterior horn that simulates a C8 RAD (Robinson and Kothari, 2020).

In relation to age, the frequency of C5 radiculopathy increased in AG 3 ($p = 0.033$); but the behavior of the other roots was similar to DIS, with a higher frequency in AG 2 (45-60 years) as the study by Kelsey et al. (1984) and Radhakrishnan et al. (1994).

As for the elements of spondylosis, there was a statistically significant correlation between the root C8 and C7-T1 osteophytes ($p = 0.010$) and with osteophytes in C5-C6 ($p=0.035$); the arthropathy was correlated with the appearance of C5 RAD ($p = 0.029$), C6 ($p = 0.046$) and C8 ($p = 0.004$); and a correlation was observed with spinal canal stenosis at the root C5 ($p = 0.016$) and C8 ($p = 0.030$), but no correlation was found with spondylolisthesis.

The main limitation for interpreting RAD diagnostic tests is the absence of a gold standard (Tullberg et al., 1993). To date, the literature has focused on comparing the diagnostic performance of MRI and EMG

Nardin et al. (1999) and Soltani et al. (2014), in patients with suspected cervical RAD, compared the MRI and EMG findings, in 27 and 31 patients, respectively. He was given a sensitivity to MRI for the diagnosis of cervical RAD of 57% and 74%; while at the EMG of 55% and 54%. They concluded that both tests were complementary to the diagnosis of RAD. According to Soltani et al. (2014), the specificity was 39% for MRI and 61% for EMG. This indicated that the diagnostic performance of the EMG was worse in patients with symptoms of more than one year from onset, clinically intermit-

tent symptoms, and whether the main symptom was pain and not weakness. However, EMG was justified in cases of discrepant clinical-radiological findings.

Lee and Lee (2012) in a retrospective study compared the diagnostic performance of both tests in suspected lumbosacral RAD. The EDX was found to be more consistent with the clinical findings, particularly with muscular weakness that was significantly correlated, with higher specificity than MRI.

Arslan et al. (2016) concluded that both tests had a degree of concordance that was significant in severe lumbar and cervical RAD, but not in mild or a moderate cervical RAD.

Singh et al. (2018) concluded that the EDX was more correlated to clinical tests than to MRI, and provides a better representation of the functional condition of muscles and nerves.

The EMG has certain limitations with false negatives under the following circumstances: in the first 20 days of acute denervation, if the compromise is sensory fibers or if it is mild, since it is a dependent observer (Wilbourn and Aminoff, 1988).

Acute denervation (positive waves and fibrillations) appears at 7-10 days in the paraspinal muscles and then in the muscles of the myotome at 2-3 weeks. The reinnervation MUAPs take 3-6 months. It may be the case to perform an exploration in which acute denervation has been resolved and reinnervation is incomplete (Wilbourn and Aminoff, 1988). In addition, like Chemali and Tsao (2005) recorded, ultimately, it depends on the patient's collaboration.

The MRI may also depend on the time of the study since there may be regression in the size of the HD during a 5 to 12-month period, or it may even completely disappear as already described Komori et al. (1996), Bush et al. (1997), and Westmark et al. (1997). Moreover, MRI has revealed that most HD are central or paracentral, but only a few affect the intervertebral foramina (Millette et al., 1991; Santiago et al., 2011). On the other hand, structural anomalies are not inexorably the cause of symptomatology (Jensen et al., 1994). The fundamental shortcoming of MRI is the lack of specificity, given that the results often fail to validate the clinical findings (Van Rijn et al., 2006) and elements of discopathy and spondylosis abound in asymptomatic patients (Rao, 2002). Without taking into account foraminal stenosis, since it is a dynamic entity that can go unnoticed on MRI, our study has found an imbalance between space-occupying injuries (C5-C6 and C6-C7) and damage to the spinal nerves (C7 and C8-T1). As Marcia Wilkinson pointed out in 1973, this may be due to the difference in length between the spinal column and the spinal cord in adulthood. Thus, the middle cervical roots already move obliquely within the vertebral canal, and the lower ones intersect with one or two intervertebral spaces before reach-

ing their intervertebral foramen. In this way, the space-occupying elements apical to the foramen would cause intermittent compression in the spinal roots, due to the biomechanical needs of the spine.

CONCLUSIONS

In short, we can say that the spondylosis has shown an obvious relationship with age, increasing progressively since the 5th decade of life, but not with the gender. Its most characteristic element is the present of osteophytes in C5-C6 level, with clear association with the C6 RAD and with the correction of the physiological lordosis.

Degenerative discopathies also tended to progressively increase with age. In contrast, the frequency of PROT and HD peaked between the ages of 50 to 60 years, before tapering off. In our sample, only PROT and HD in C3-C4 have significance with gender, being more frequent in males.

The highest frequency of RAD was observed between the ages of 50 to 60 years, with C7 being the most affected root, and with significance with gender, being more frequent in males. Neither PROT nor HD were related to RAD in any of the levels examined.

Given the abundance of neurogenic findings in muscles dependent on the C8-T1 roots and the few space-occupying lesions at the C7-T1 level, our retrospective case series study is the first to suggest, with a large sample size, that lower cervical roots are damaged within the vertebral canal by space-occupying lesions cranial to the intervertebral foramen, since the roots exit the spinal cord obliquely and descend into the vertebral canal.

LIST OF ABBREVIATIONS

AG – Age group
 DC - Osteophytes
 DIS - Discopathy
 EDX- Electrodiagnostic
 EMG – Electromyography
 ENG - Nerve conduction studies
 HD – Disc herniation
 MRI – Magnetic resonance imagen
 MUAPs – Motor unit potentials
 PROT – Disc protrusion
 RAD – Radiculopathy
 SD – Standar deviation

ACKNOWLEDGEMENTS

To Dr. Miguel Ángel Reina Perticone, for advice on the design and layout of the article.

REFERENCES

- ADAMS MA, LAMA P, ZEHRA U, DOLAN P (2015) Why do some intervertebral discs degenerate, when others (in the same spine) do not? *Clin Anat*, 28(2): 195-204.
- AMERICAN ASSOCIATION OF ELECTRODIAGNOSTIC MEDICINE (1999) Practice parameter for needle electromyographic evaluation of patients with suspected cervical radiculopathy: Summary statement. *Muscle Nerve*, 22: 209-211.
- ARSLAN Y, YASAR E, ZORLU Y (2016) Correlation of electromyography and magnetic resonance imaging findings in the diagnosis of suspected radiculopathy. *Turk J Neurol*, 22: 55-59.
- BENDILAYI IC, GUZEL R, TATLI U, SALIMOV F, KECALI O (2020) The relationship between neck pain and cervical alignment in patients with temporomandibular disorders. *Cranio*, 38(3): 174-179.
- BROWN BM, SCHWARTZ RH, FRANK E, BLANK NK (1988) Preoperative evaluation of cervical radiculopathy and myelopathy by surface-coil MR imaging. *AJR Am J Roentgenol*, 151: 1205-1212.
- BUSH K, CHAUDHURI R, HILLIER S, PENNY J (1997) The pathomorphologic changes that accompany the resolution of cervical radiculopathy. A prospective study with repeat magnetic resonance imaging. *Spine (Phila Pa 1976)*, 22: 183-186; discussion 187.
- CARETTE S, FEHLINGS MG (2005) Clinical practice. Cervical radiculopathy. *N Engl J Med*, 353: 392-399.
- CHEMALI KR, TSAO B (2005) Electrodiagnostic testing of nerves and muscles: When, why, and how to order. *Cleve Clin J Med*, 72: 37-48.
- CHIBA K, OGAWA Y, ISHII K, TAKAISHI H, NAKAMURA M, MARUIWA H, MATSUMOTO M, TOYAMA Y (2006) Long-term results of expansive open-door laminoplasty for cervical myelopathy--average 14-year follow-up study. *Spine (Phila Pa 1976)*, 31: 2998-3005.
- DEVEREAUX M (2009) Neck pain. *Med Clin North Am*, 93: 273-284.
- DILLINGHAM TR, LAUDER TD, ANDARY M, KUMAR S, PEZZIN LE, STEPHENS RT, SHANNON S (2001) Identification of cervical radiculopathies: Optimizing the electromyographic screen. *Am J Phys Med Rehabil*, 80: 84-91.
- EZRA D, HERSHKOVITZ I, SALAME K, ALPEROVITCH-NAJENSON D, SLON V (2019) Osteophytes in the cervical vertebral bodies (C3-C7)-demographical perspectives. *Anat Rec (Hoboken)*, 302: 226-231.
- FARDON DF, WILLIAMS AL, DOHRING EJ, MURTAGH FR, ROTHMAN SL, SZE GK (2014) Lumbar disc nomenclature: version 2.0: Recommendations of the combined task forces of the North American Spine Society, the American Society of Spine Radiology and the American Society of Neuroradiology. *Spine J*, 14 (11): 2525-2545.
- FOUYAS IP, STATHAM PF, SANDERCOCK PA (2002) Cochrane review on the role of surgery in cervical spondylotic radiculomyelopathy. *Spine (Phila Pa 1976)*, 27: 736-747.
- GROB D, FRAUENFELDER H, MANNION AF (2007) The association between cervical spine curvature and neck pain. *Eur Spine J*, 16: 669-678.
- HADLEY LA (1957) The covertebral articulations and cervical foramen encroachment. *J Bone Joint Surg*

- Am, 39: 910-920.
- HARRISON DE, HARRISON DD, JANIK TJ, JONES EW, CAILLIET R, NORMAND M (2001) Comparison of axial and flexural stresses in lordosis and three buckled configurations of the cervical spine. *Clin Biomech (Bristol, Avon)*, 16: 276-284.
- HEHIR MK, FIGUEROA JJ, ZYNDA-WEISS AM, STANTON M, LOGIGIAN EL (2012) Unexpected neuroimaging abnormalities in patients with apparent C8 radiculopathy: Broadening the clinical spectrum. *Muscle Nerve*, 45: 859-865.
- HELLER JG (1992) The syndromes of degenerative cervical disease. *Orthop Clin N Am*, 23(3): 381-394.
- HEY H, TEO A, LAU L (2016) Cervical spine sagittal alignment is different in standing and sitting: Are these changes predictable. In: 23rd International Meeting on Advanced Spine Techniques. Washington, DC.
- HEY HWD, LAU ET, WONG GC, TAN KA, LIU GK, WONG HK (2017) Cervical alignment variations in different postures and predictors of normal cervical kyphosis: A new understanding. *Spine (Phila Pa 1976)*, 42: 1614-1621.
- HOEFER PFA, GUTTMAN SA (1944) Electromyography as a method for determination of level of lesions in the spinal cord. *Arch Neurol Psychiatry*, 51: 415-422.
- IYER S, KIM HJ (2016) Cervical radiculopathy. *Curr Rev Musculoskelet Med*, 9: 272-280.
- JENSEN MC, BRANT-ZAWADZKI MN, OBUCHOWSKI N, MODIC MT, MALKASIAN D, ROSS JS (1994) Magnetic resonance imaging of the lumbar spine in people without back pain. *N Engl J Med*, 331: 69-73.
- KELSEY JL, GITHENS PB, WALTER SD, SOUTHWICK WO, WEIL U, HOLFORD TR, OSTFELD AM, CALOGERO JA, O'CONNOR T, WHITE AA 3rd (1984) An epidemiological study of acute prolapsed cervical intervertebral disc. *J Bone Joint Surg Am*, 66: 907-914.
- KIM DK, KIM MJ, KIM YS, OH CS, SHIN DH (2012) Vertebral osteophyte of pre-modern Korean skeletons from Joseon tombs. *Anat Cell Biol*, 45: 274-281.
- KOMORI H, SHINOMIYA K, NAKAI O, YAMAURA I, TAKEDA S, FURUYA K (1996) The natural history of herniated nucleus pulposus with radiculopathy. *Spine (Phila Pa 1976)*, 21: 225-229.
- LEE HY, CHUNG IH, SIR WS, KANG HS, LEE HS, KO JS, LEE MS, PARK SS (1992) Variations of the ventral rami of the brachial plexus. *J Korean Med Sci*, 7: 19-24.
- LEE JH, LEE SH (2012) Physical examination, magnetic resonance image, and electrodiagnostic study in patients with lumbosacral disc herniation or spinal stenosis. *J Rehabil Med*, 44: 845-850.
- LESTINI WF, WIESEL SW (1989) The pathogenesis of cervical spondylosis. *Clin Orthop Relat Res*, 239: 69-93.
- MANIFOLD SG, MCCANN PD (1999) Cervical radiculitis and shoulder disorders. *Clin Orthop Relat Res*, 368: 105-113.
- MCVINEY J, SCHULZ D, BOCK R, HARRISON DE, HOLLARD B (2005) Determining the relationship between cervical lordosis and neck complaints. *J Manipulative Physiol Ther*, 28: 187-193.
- MILETTE PC, MELANCON D, DUPUIS PR, VADEBONCOEUR R, BERTRAND G, PELLETIER JP, RAYNAULD JP (1991) A simplified terminology for abnormalities of the lumbar disk. *Can Assoc Radiol J*, 42: 319-325.
- MINK JH, GORDON RE, DEUTSCH AL (2003) The cervical spine: Radiologist's perspective. *Phys Med Rehabil Clin*, 14: 493-548.
- NARDIN RA, PATEL MR, GUDAS TF, RUTKOVE SB, RAYNOR EM (1999) EMG and MRI in the evaluation of radiculopathy. *Muscle Nerve*, 22: 151-155.
- NATHAN H (1962) Osteophytes of the vertebral column: An anatomical study of their development according to age, race, and sex with considerations as to their etiology and significance. *JBJS*, 44: 243-268.
- OKADA E, MATSUMOTO M, ICHIHARA D, CHIBA K, TOYAMA Y, FUJIWARA H, MOMOSHIMA S, NISHIWAKI Y, HASHIMOTO T, OGAWA J, WATANABE M, TAKAHATA T (2009) Does the sagittal alignment of the cervical spine have an impact on disk degeneration? Minimum 10-year follow-up of asymptomatic volunteers. *Eur Spine J*, 18: 1644-1651.
- PATEL EA, PERLOFF MD (2018) Radicular pain syndromes: Cervical, lumbar, and spinal stenosis. *Semin Neurol*, 38: 634-639.
- PÉREZ MS, SIERRA AG, MARTÍN AS, GÓMEZ PG, BOO DP (2012) Nomenclatura estandarizada de la patología discal. *Radiología*, 54: 503-512.
- POSTACCHINI F (2001) Lumbar disc herniation: A new equilibrium is needed between nonoperative and operative treatment. *Spine (Phila Pa 1976)*, 26: 601.
- RADHAKRISHNAN K, LITCHY WJ, O'FALLON WM, KURLAND LT (1994) Epidemiology of cervical radiculopathy. A population based study from Rochester, Minnesota, 1976 through 1990. *Brain*, 117(2): 325.
- RAO R (2002) Neck pain, cervical radiculopathy, and cervical myelopathy: Pathophysiology, natural history, and clinical evaluation. *J Bone Joint Surg Am*, 84: 1872-1881.
- ROBINSON J, KOTHARI MJ (2020) Clinical features and diagnosis of cervical radiculopathy. In: Shefner JM (ed). *UpToDate*. Waltham, Massachusetts: UpToDate.
- ROH JS, TENG AL, YOO JU, DAVIS J, FUREY C, BOHLMAN HH (2005) Degenerative Disorders of the Lumbar and Cervical Spine. *Orthop Clin N Am*, 36: 255-262.
- SANTIAGO FR, GARCÍA MC, ÁLVAREZ LG, MORENO MT (2011) Tomografía computarizada y resonancia magnética en las enfermedades dolorosas del raquis: Aportaciones respectivas y controversias. *Radiología*, 53: 116-133.
- SCHEER JK, TANG JA, SMITH JS, ACOSTA FL Jr, PROTOPSALTIS TS, BLONDEL B, BESS S, SHAFREY CI, DEVIREN V, LAFAGE V, SCHWAB F, AMES CP, International Spine Study Group (2013) Cervical spine alignment, sagittal deformity, and clinical implications: A review. *J Neurosurg Spine*, 19: 141-159.
- SINGH R, YADAV SK, SOOD S, YADAV RK, ROHILLA

- R (2018) Evaluation of the correlation of magnetic resonance imaging and electrodiagnostic findings in chronic low backache patients. *Asian J Neurosurg*, 13: 1078-1083.
- SOLTANI ZR, SAJADI S, TAVANA B (2014) A comparison of magnetic resonance imaging with electrodiagnostic findings in the evaluation of clinical radiculopathy: A cross-sectional study. *Eur Spine J*, 23: 916-921.
- STAFFORD MA, MENG P, HILL DA (2007) Sciatica: A review of history, epidemiology, pathogenesis, and the role of epidural steroid injection in management. *Br J Anaesth*, 99: 461-473.
- TAKESHIMA T, OMOKAWA S, TAKAOKA T, ARAKI M, UEDA Y, TAKAKURA Y (2002) Sagittal alignment of cervical flexion and extension: Lateral radiographic analysis. *Spine (Phila Pa 1976)*, 27: E348-E355.
- TULLBERG T, SVANBORG E, ISACCSSON J, GRANE P (1993) A preoperative and postoperative study of the accuracy and value of electrodiagnosis in patients with lumbosacral disc herniation. *Spine (Phila Pa 1976)*, 18: 837-842.
- UYSAL II, SEKER M, KARABULUT AK, BUYUKMUMCU M, ZIYLAN T (2003) Brachial plexus variations in human fetuses. *Neurosurgery*, 53: 676-684.
- VAN RIJN JC, KLEMETSO N, REITSMA JB, MAJOIE CB, HULSMANS FJ, PEUL WC, BOSSUYT PM, DEN HEETEN GJ, STAM J (2006) Symptomatic and asymptomatic abnormalities in patients with lumbosacral radicular syndrome: Clinical examination compared with MRI. *Clin Neurol Neurosurg*, 108: 553-557.
- VERTINSKY AT, KRASNOKUTSKY MV, AUGUSTIN M, BAMMER R (2007) Cutting-edge imaging of the spine. *Neuroimaging Clin N Am*, 17: 117-136.
- WAINNER RS, GILL H (2000) Diagnosis and nonoperative management of cervical radiculopathy. *J Orthop Sports Phys Ther*, 30: 728-744.
- WEBER J, CZARNETZKI A, SPRING A (2003) Paleopathological features of the cervical spine in the early middle ages: Natural history of degenerative diseases. *Neurosurgery*, 53: 1418-1423.
- WESTMARK RM, WETSMARK KD, SONNTAG VK (1997) Disappearing cervical disc. Case report. *J Neurosurg*, 86: 289-290.
- WILBOURN AJ, AMINOFF MJ (1988) The electrophysiologic examination in patients with radiculopathies. *Muscle Nerve*, 11: 1099-1114.
- WILKINSON M. *Espondilosis Cervical*. Barcelona: Salvat; 1973
- YOON SH (2011) Cervical radiculopathy. *Phys Med Rehabil Clin N Am*, 22: 439-446.