

## Case Report

# Three-dimensional bone evaluation after surgical treatment with plasma rich in growth factors of Medication Related Osteonecrosis of the Jaw (MRONJ): A report of 3 cases

Simón Pardiñas López<sup>a,e,\*</sup>, Oreste Iocca<sup>d</sup>, Ismael Khouly<sup>b,c</sup>

<sup>a</sup> Periodontology and Oral Surgery, Clínica Médico Dental Pardiñas, Real 66, 3<sup>o</sup>, 15003 A Coruña, Spain

<sup>b</sup> Bluestone Center for Clinical Research, 421 First Avenue, 2nd Floor, New York, NY 10010-4086, United States of America

<sup>c</sup> Department of Oral and Maxillofacial Surgery, New York University College of Dentistry, 421 First Avenue, 2nd Floor, New York, NY 10010-4086, United States of America

<sup>d</sup> Department of Otolaryngology-Head and Neck Surgery, Humanitas Clinical and Research Hospital, Rozzano, Milano, Italy

<sup>e</sup> Cell Therapy and Regenerative Medicine Group, Centre for Advanced Scientific Research (CICA) and Biomedical Research Institute of A Coruña (INIBIC) strategic group, Universidade da Coruña (UDC), University Hospital Complex of A Coruña (CHUAC), Galician Health Service (SERGAS); A Coruña, Spain

## ARTICLE INFO

## Keywords:

3D  
Growth factors  
Bone remodeling  
Bisphosphonates  
Osteonecrosis

## ABSTRACT

**Introduction:** Medication Related Osteonecrosis of the Jaw (MRONJ) is an adverse effect of antiresorptive and antiangiogenic agents that consists of progressive bone destruction in the maxillofacial area. The purpose of this study is to analyze the effect on bone volume of a surgical protocol using plasma rich in growth factors (PRGF) for successfully treating MRONJ.

**Methods:** Three patients were treated combining surgical debridement with PRGF. Cone beam computed tomography scans were taken prior to surgery and 12 months after to measure bone volume changes. Biopsies were taken for histology analysis during surgery.

**Results:** All patients showed a complete soft tissue and bone healing with pain, discomfort, and neural symptoms resolution for a follow up period of 30 months. A total of 12 to 30% of bone volume gain was found at 12 months after surgery.

**Conclusions:** PRGF in combination with surgery may be effective in treating MRONJ. Future trials must be performed to confirm these results, including bone volume analysis.

## 1. Introduction

Medication-related osteonecrosis of the jaw (MRONJ) is clinically characterized by an avascular area of non-healing necrotic bone in the maxillofacial area that has persisted for longer than 8 weeks, with or without exposed bone, in patients exposed to antiresorptive and antiangiogenic drug treatment with no evidence of metastatic disease in the jaw and no history of craniofacial radiation (Ruggiero et al., 2006; Ruggiero et al., 2014; Del Fabbro et al., 2015). Other clinical signs such as mucosal swelling, abscesses and diffuse pain have also been described (Fliefel et al., 2015). If left untreated, the lesion can progress and end up with neural involvement with altered sensation, oro-antral or oro-nasal communications, fistulae or mandibular fractures (Mozzati et al., 2012a).

The management of patients with MRONJ is still challenging. The goal of treatment of these patients is the preservation of quality of life

by eliminating pain, managing infection, stopping the progression of the necrosis and preventing the development of new areas of necrosis (Ruggiero et al., 2006; Del Fabbro et al., 2015; Fliefel et al., 2015; Adornato et al., 2007; Del Fabbro et al., 2014; Marx et al., 2005; Vescovi et al., 2010; Ruggiero, 2013). Treatment strategies such as administrations of antibiotics, antibacterial mouth rinse, surgical debridement, cessation of antiresorptive medication, pain control, hyperbaric oxygen therapy, laser appliance, covering exposed areas with local flaps or growth factors, among others, have been described (Fliefel et al., 2015; Vescovi et al., 2010; Pelaz et al., 2014; Gallego et al., 2012; Martins et al., 2012). However, there is currently no gold standard treatment for MRONJ.

Recently, treatments that enhance wound healing by using growth factors have opened a promising way to successfully treat this medical condition (Del Fabbro et al., 2015; Mozzati et al., 2012a; Adornato et al., 2007; Martins et al., 2012; Lopez-Jornet et al., 2016; Anitua et al.,

\* Corresponding author.

E-mail addresses: [s.pardinas@clinicapardinas.com](mailto:s.pardinas@clinicapardinas.com) (S. Pardiñas López), [iek3@nyu.edu](mailto:iek3@nyu.edu) (I. Khouly).

<https://doi.org/10.1016/j.bonr.2019.100208>

Received 2 January 2019; Received in revised form 22 April 2019; Accepted 2 May 2019

Available online 03 May 2019

2352-1872/ © 2019 The Authors. Published by Elsevier Inc. This is an open access article under the CC BY-NC-ND license (<http://creativecommons.org/licenses/by-nc-nd/4.0/>).

2013; Lee et al., 2007b; Curi et al., 2007). The use of autologous growth factors, such as plasma rich in growth factors (PRGF), has demonstrated the potential to influence healing bone and soft tissue defects (Marx et al., 1998). PRGF is an autologous platelet-enriched plasma obtained from the patient's own blood. This material releases active proteins that can influence and promote cell recruitment, growth, and differentiation, stimulate the production of collagen and improve soft and hard tissue wound healing. The PRGF has been used during the treatment and as a prevention alternative for MRONJ (Del Fabbro et al., 2015; Scoletta et al., 2013; Mozzati et al., 2012b). In this sense, one case report and one case series reported success of all treated cases with soft tissue closure without clinical or radiographic signs of infection and with a complete neural recovery when inferior dental nerve was involved (Mozzati et al., 2012a; Anitua et al., 2013). Similarly, previous systematic reviews reported better outcomes in terms of wound healing and stage diagnosis changes of MRONJ (Del Fabbro et al., 2015; Fliefel et al., 2015) when autologous growth factors were used in comparison to when no autologous growth factors were used. However, there is still limited information related to any bone formation after treatment of MRONJ, and although previous studies radiographically reported bone remodeling after surgically treating MRONJ in combination with growth factors (Anitua et al., 2013; Curi et al., 2007), to the author's knowledge no bone changes quantification has been made yet in the literature.

Therefore, the aim of this study is to analyze the effect of a surgical treatment protocol for MRONJ using PRGF on bone volume changes. Moreover, this study will describe the surgical protocol used to obtain complete healing, remission of all pathologic signs and symptoms in 3 patients.

## 2. Cases presentation

Between March 2014 and January 2016, 3 patients were referred to a Private Practice in A Coruña, Spain, for treatment of MRONJ associated with bisphosphonate use. The diagnosis of MRONJ was based on the criteria of nonhealing necrotic exposed or non-exposed bone in the mandible for at least 2 months in patients who had received anti-resorptive medication, and with no history of head and neck radiotherapy (Ruggiero et al., 2014; Kim et al., 2015). Written and oral consent was obtained from all patients included in the study.

The present study was written following the CARE Guidelines for Case Reports (Gagnier et al., 2013). This study is exempt of being reviewed by an ethical committee as it is a retrospective case report study. All procedures followed were in accordance with the Helsinki Declaration.

### 2.1. Patient characteristics

#### 2.1.1. Case 1

A 67-year-old woman, heavy smoker, with a 20-year history of treatment of breast cancer with mastectomy surgery, radiotherapy, and chemotherapy with Tamoxifen, Paclitaxel and Carboplatin; and treated with Exemestane (25 mg/day), Fulvestrant (250 mg/day) Everolimus (2.5 mg/day) and Zoledronate (Zometa®; 4 mg intravenously monthly for 6 years); had a non-healing post-extraction socket 3 months after a dental extraction of the first lower left molar. Intraoral examination showed exposed necrotic avascular bone of 9 mm in length on the mandibular alveolar ridge. (Fig. 1A) The lesion was classified as stage 2 according to the American Association of Oral and Maxillofacial Surgeons (AAOMS) (Ruggiero et al., 2014).

Bisphosphonate therapy was interrupted before the surgical procedure due to patient's own decision in accordance to the patient's physician.

#### 2.1.2. Case 2

A 61-year-old woman with a history of heavy smoking, early

menopause and use of oral BPs.

(Risedronate 50 mg/week from 2008 to 2011) presented a peri-implant lesion around an implant in the first left mandible premolar area. The implant was successful for 10 years and the patient presented for implant maintenance once a year. However, a marginal bone loss of 3 mm was radiographically noticed in the previous 12 months (2015). (Figs. 2-A, B) In 2016, intraoral examination showed inflammation of the soft tissue around implants. Bleeding and suppuration on probing was also present. The patient was scheduled for implant removal. Two months after implant removal, the area showed avascular exposed bone to the oral cavity and presented intense dysesthesia. Patient also complained about intense pain referred to the ear and eye. At this point we suspected that the patient was or had been under antiresorptive medication, which was confirmed by her physician. The lesion was classified as stage 2 according to the American Association of Oral and Maxillofacial Surgeons (AAOMS). (Ruggiero et al., 2014) The patient was then scheduled for surgical debridement of the necrotic bone and regeneration with PRGF. At the time of the surgery the patient was not under bisphosphonate therapy.

#### 2.1.3. Case 3

An 80-year-old woman with history of use of Ibandronate orally (150 mg/month for 3 years) presented with pain and gingival inflammation in the lower right molar area 3 months after a dental extraction. Oral examination showed fistula with pus drainage and erythema of the surrounding soft tissues. The patient had symptoms that included pain and swelling. The lesion was classified as stage 2 according to the American Association of Oral and Maxillofacial Surgeons (AAOMS) (Ruggiero et al., 2014).

Bisphosphonate therapy was interrupted before the surgical procedure due to patient's own decision in accordance to the patient's physician.

#### 2.1.4. Surgical procedure

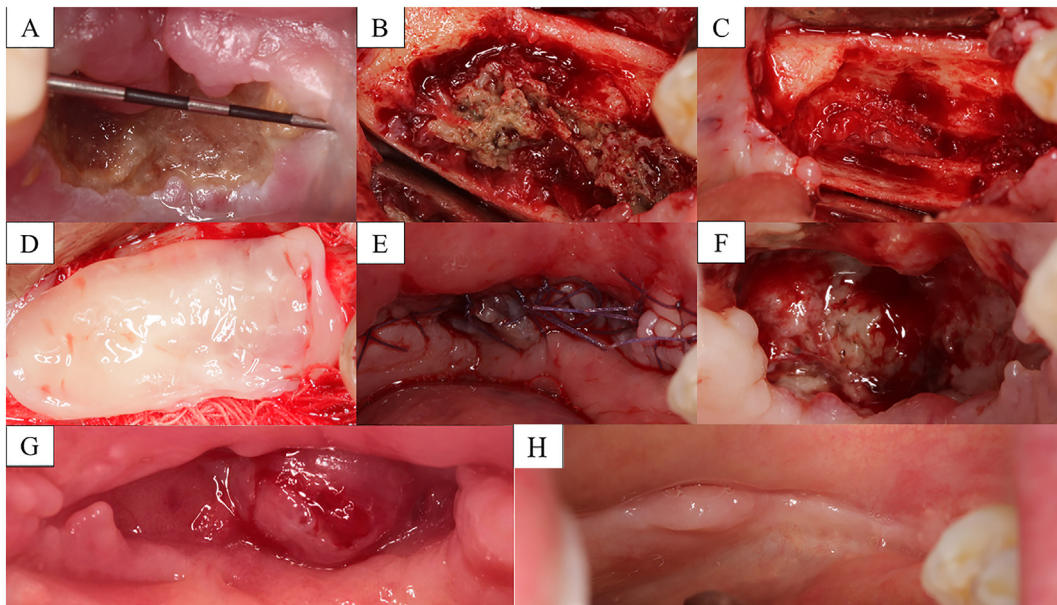
All surgical procedures and follow-up visits were performed by the same professional (SPL) at the Clínica Médico Dental Pardiñas in A Coruña, Spain. Prior to any treatment, all patients signed a consent form regarding the surgical therapy using PRGF. Prophylactic antibiotics (Amoxicillin 2000 mg) were administered orally 1 h before surgery.

Local anesthesia (Articaine 40 mg and 1% epinephrine) was administered. A full thickness buccal mucoperiosteal flap and reflection of the lingual mucosa was performed without vertical releasing incisions. All granulation tissue and necrotic bone were removed using a round bur under saline irrigation, leaving bleeding margins and smoothing any sharp bony edges. Samples of necrotic bone were sent for histopathologic examination to rule out a metastatic lesion and to identify specific microorganisms.

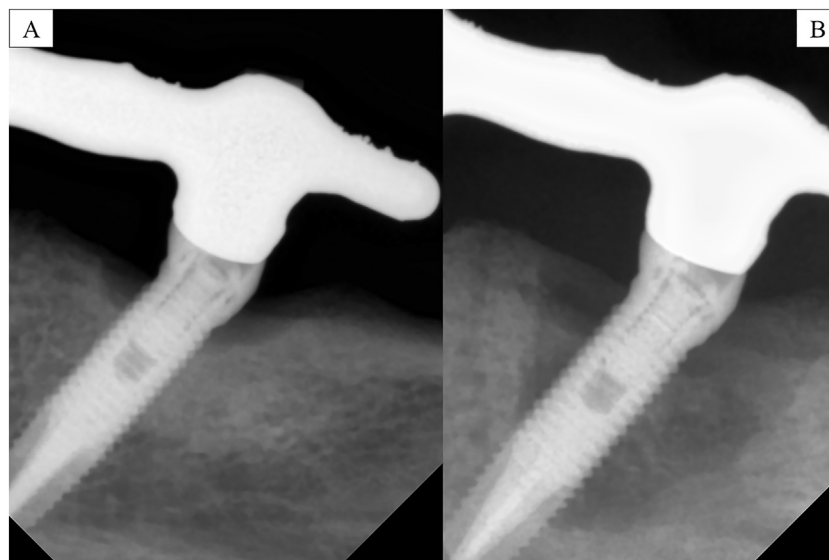
Twenty minutes prior to surgery, PRGF was obtained from the patient's own blood following the protocol described by Anitua et al. (Anitua et al., 2009). After bone debridement, a PRGF clot was applied to fill the bony defect and it was covered by a PRGF membrane. The region was sutured with primary closure using 4-0 polyglycolic acid (GLYCOLON® RESORBA Medical GmbH, Nuremberg, Germany) (Fig. 1-B, C, D, E) (Case 1), (Fig. 3-A, B, C) (Case 2) Activated PRGF liquid was injected into the soft tissue margins around the treated area using a sterile 1 ml syringe (RAYS S.P.A., Osimo, Italy) to stimulate healing of gingival ulceration and wound closure (Anitua et al., 2013).

Antibiotic therapy with Amoxicillin (500 mg 3 times a day) was maintained for 10 days in Cases 2 and 3, while in Case 1 it was maintained for 21 days until complete epithelium closure was achieved.

Written instructions were given to the patient for proper oral hygiene and maintenance of the surgical site.



**Fig. 1.** Case 1. A) Intraoral picture showing the extension of the mandibular area affected. B) Necrotic bone in the mandibular molar area. C) Aspect of the area after removal of the necrotic bone. Note the presence of the inferior alveolar nerve exposed to the oral cavity. D) Affected area covered with a PRGF membrane. E) Primary closure of the wound with sutures. F) Epithelium and new blood vessels growing in the treated area. G) Intraoral picture 21 days after surgical treatment showing new formed epithelium. H) Intraoral picture taken 12 months after surgical treatment that shows complete healing.



**Fig. 2.** Case 2. A) Periapical x-ray taken in January 2015. B) Periapical x-ray taken in January 2016 showing the extent of the lesion.

## 2.2. Radiologic examination and bone changes

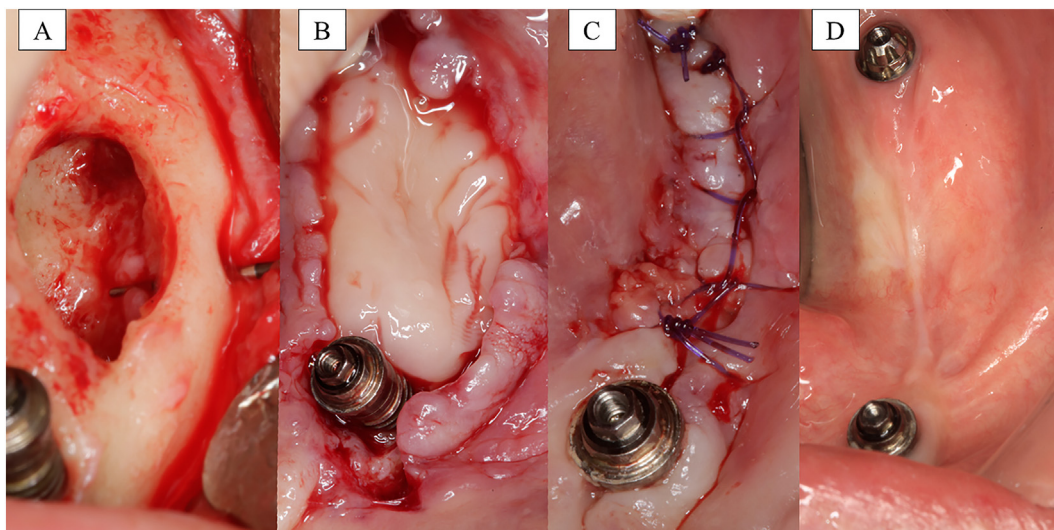
Cone beam computerized tomography (CBCT) scans were taken prior to any surgical intervention. A Carestream 9300 CS Scan (Carestream Health, USA) was used to obtain images. The parameters used were 90 kV and 5 mA with a FOV of 17x11cm. The second CBCT scan was taken 12 months after surgery. CBCT was taken with the patient supine and with the head centered and immobilized sponge pads on each side of the temporal region. Patients were instructed not to move, swallow, or chew during the acquisition process. DICOM data were then imported into a 3D dental implant planning software (NemoStudio, Nemotec, Spain), where two trained examiners (SPL [Oral Surgeon] and ADF [Prosthodontist]) selected the same areas of interest by using anatomic landmarks in two separate occasions to ensure intra-examiner reliability. 3D STL files were then created from

each DICOM files using the same software and the same parameters (NemoStudio, Nemotec, Spain). Both STL files of pre and post treatment were sent for analysis to MadMouse Studio Visual Medics (MadMouse Studio, Zaragoza, Spain), where a blinded 3D designer combined them using the software 3Ds Max (Autodesk, Inc., USA) to compare the volume changes.

## 2.3. Neural considerations

To measure neural changes, the protocol based on Zuniga and Essick (Zuniga, 1992) was followed (Zuniga, 1992; Bhat and Cariappa, 2012). The patients were asked to describe any changes in the sensation over the face. Then the area that the patient referred as abnormal was mapped. This was performed by touching with the tip of a periodontal probe starting around the areas where the patient felt a normal





**Fig. 3.** Case 2. A) Debrided area showing involvement of inferior alveolar nerve and mental foramen. B) PRGF membrane placed filling the defect. C) Primary closure with sutures. D) Intraoral picture 12 months after surgical treatment showing complete healing.

sensation. If not, the stimulus was moved until the patient felt a normal sensation. An area inside which the patient had altered sensation was marked with blue dots. (Fig. 5-A, B).

#### 2.4. Histological analysis

Immediately after harvesting, the bone biopsies were submerged in a 10% neutral buffered formalin solution for fixation. After demineralization with formic acid 9:1 solution, cores were dehydrated and embedded in paraffin, sectioned to 5  $\mu$ m thickness along the length of the core using a microtome Leica RM 2145 (Leica Microsystems Inc., Wetzlar, Germany). Samples were stained with a conventional hematoxylin and eosin technique and prepared for histologic analysis to evaluate bone destruction, presence of pathogens and inflammatory tissue.

### 3. Results

#### 3.1. Healing parameters

All cases had a successful recovery and were followed up for 30 months. Success of the treatment was evaluated as healing of MRONJ, with healed oral mucosa and no exposed bone to the oral cavity, absence of pain and discomfort, without signs of infection and signs of bone remodeling when radiographically analyzed at the follow up visits. All the patients adhere and complied to the treatment and follow up visits as indicated by the clinician.

##### 3.1.1. Case 1

The postoperative follow-up 7 days after surgery showed partial healing of the surgical site, with an apical layer of newly forming epithelium. (Fig. 1-F). At 21 days follow-up the area showed good healing with newly formed epithelium and no presence of infection. (Fig. 1-G) The patient referred no pain or discomfort and started to have signs of nerve function recovering. The patient presented for follow-up every 3 months after surgery for 30 months without any signs of recurrence. (Fig. 1-H).

##### 3.1.2. Case 2

At the follow up visit 14 days after surgery, the area showed a thin layer of new epithelium covering most parts of the affected area. At 24 days follow-up, new epithelium covered the whole area, and at 2 months follow-up the area was completely healed. Patient came for

follow up every 3 months for 30 months. (Fig. 3-D).

##### 3.1.3. Case 3

At 14-day follow-up, the area was completely closed with keratinized epithelium and symptoms of pain and discomfort disappeared. Patient came to follow-up every 3 months for 30 months.

#### 3.2. Radiographical analysis

Comparison of the 3D STL files obtained from the CBCT confirmed the presence of more bone volume after treatment, showing a volume of 4,085,309.24 cubic units before treatment and 5,763,392.05 cubic units after treatment, which represents a 30%  $\pm$  7.5% of volume gained for Case 1, (Fig. 4-A, B, C); a volume of 2,283,944.49 cubic units before treatment and 2,969,332.80 cubic units after treatment, which represents a 23.10%  $\pm$  7.5% of volume gained for Case 2; and a volume of 1,465,547.42 cubic units before treatment and 1,670,238.30 cubic units after treatment, which represents a 12.30%  $\pm$  7.5% of volume gained for Case 3.

#### 3.3. Neural considerations

##### 3.3.1. Case 1

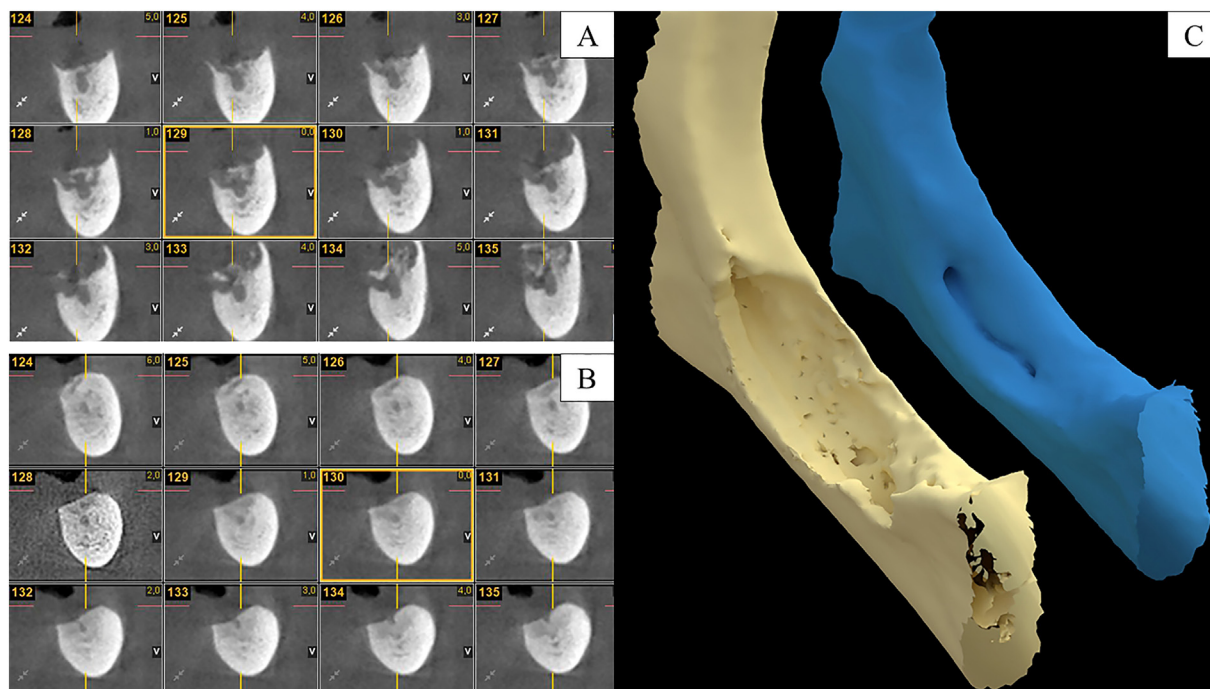
Extraoral examination showed paresthesia of the left mental area (Fig. 5-A) and the patient complained about feeling severe pain, discomfort on chewing, halitosis, and pins and needles sensation. CBCT scan showed destruction of the alveolar bone with affection of the inferior alveolar nerve. (Fig. 4-A).

At 14 days follow-up, the patient referred no pain or discomfort and started to have signs of nerve function recovering.

At 6 months follow-up, the area with paresthesia improved considerably. At 12 months follow-up, the patient recovered the sensitivity almost completely and only complained about a small area in the lip without sensation. (Fig. 5-B).

##### 3.3.2. Case 2

Extraoral and intraoral examination showed intense dysesthesia with hyperalgesia and hyperpathia on the left side of the mandible. Patient also complained about intense pain that was referred to the left ear and eye, which was not relieved with pain medication. CBCT scan showed inferior alveolar nerve involvement. At the follow-up visit 14 days after surgery, no pain or discomfort was referred by the patient. The neuropathic symptoms of nerve affection disappeared.



**Fig. 4.** Case 1. A) CBCT section of the area affected. Note the involvement of the inferior alveolar nerve. B) CBCT taken 12 months after surgery. Note the bone remodeling around inferior alveolar nerve. C) 3D STL file comparing bone volume before treatment (yellow) and 12 months after treatment (blue). Comparison shows 4,085,309.24 cubic units before treatment and 5,763,392.05 cubic units after treatments, which represents a 30% + –7.5% of volume gained. (For interpretation of the references to colour in this figure legend, the reader is referred to the web version of this article.)

3.3.3. Case 3

At 14-day follow-up visit, the patient referred no symptoms of pain and discomfort.

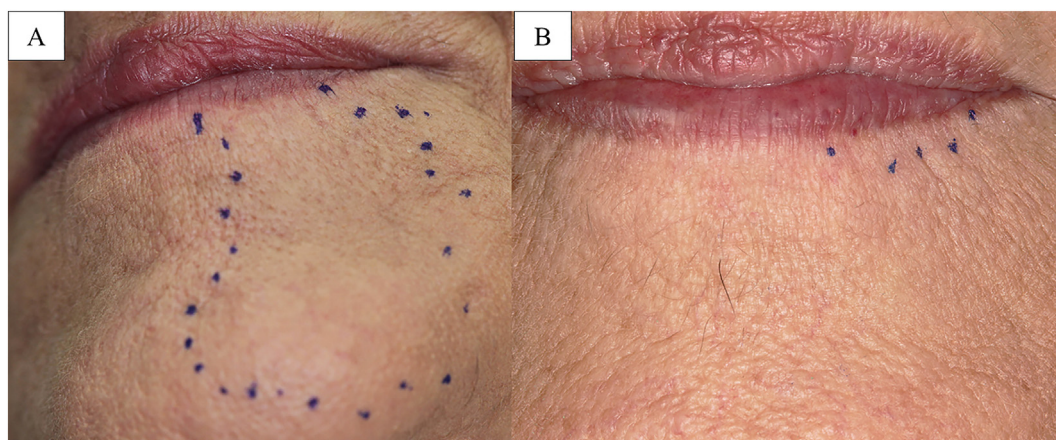
3.4. Histological examination

The histopathologic examinations showed partial destruction of bone with no evidence of metastatic disease, presence of fibrous tissue and thick colonies of Actinomyces and leucocyte neutrophil infiltrates. (Fig. 6) No other type of malignancies was identified. A diagnosis of Actinomycosis and MRONJ was confirmed for all the cases.

4. Discussion

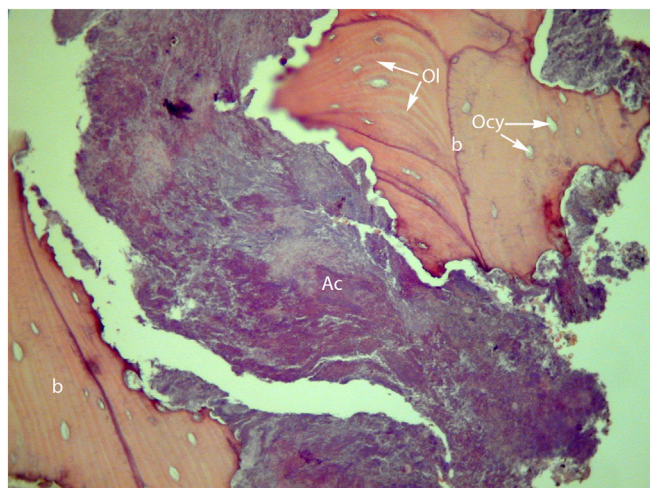
There are several theories regarding the pathophysiology of MRONJ such as local infection and micro-damage, disruption in the bone

remodeling process involving osteoblasts and osteoclasts, suppressed angiogenesis and bisphosphonate's direct toxicity to soft tissue and bone (Del Fabbro et al., 2015; Anitua et al., 2013; Abu-Id et al., 2008). This may lead to bone necrosis and ulceration of the mucosa with subsequent exposure, which would be an open path to bacterial contamination. MRONJ may result from a combination of these mechanisms (Fliefel et al., 2015; Abu-Id et al., 2008). Also, being that only a small number of patients exposed to anti-resorptive agents develops MRONJ, some authors postulated a possible pharmacogenetic factor relation (Del Fabbro et al., 2015). Intravenous bisphosphonates such as Zoledronate are much more frequently associated with MRONJ than oral bisphosphonates like Risedronate or Ibandronate, due to the more potent inhibitory effect and higher activity of bone remodeling (Fliefel et al., 2015; Abu-Id et al., 2008; Katz and Ordoveza, 2014). Moreover, a longer duration of the treatment and higher doses have been related as risk factors for developing MRONJ (Lopez-Jornet et al., 2016; Katz and



**Fig. 5.** Case 1. A) Extraoral picture that shows the extension of the area with paresthesia (area inside the dots) before treatment B) Extraoral picture that shows the extension of the area with paresthesia (area inside the dots) 12 months after treatment. Note the improvement 12 months after surgery.





**Fig. 6.** Cross-section of a core sample showing areas of bone (b) with evident destruction. Colonies of Actinomyces can be observed in the center of the image (Ac), occupying the space where healthy bone should be. “ocy” indicates osteocyte; “Ol” indicates Ossifying lines. (Hematoxylin and eosin; 100×).

Ordoveza, 2014). In the present study, one of the patients that had the most severe MRONJ was under Zolendronate medication, whereas the other two patients were under Risendronate or Ibandronate medication. Some studies recommend, as a minimum, cessation of bisphosphonate therapy when osteonecrosis of the jaw (ONJ) occurs and if surgical treatment is indicated (Curi et al., 2007; Abu-Id et al., 2008), although there is currently no evidence whether or not there is any benefit on interrupting the bisphosphonate therapy. It should be outweighed the risk of skeletal complications versus the risk of further avascular osteonecrosis (Curi et al., 2007). In the present study, two of the patients were under bisphosphonate medication when ONJ occurred.

A higher incidence of MRONJ has been reported in patients with systemic conditions, especially those with multiple myeloma, breast cancer, kidney diseases, autoimmune diseases and medication therapy like corticosteroids and chemotherapy that lead to immunosuppression, inflammatory inhibition and delayed wound healing (Fliefel et al., 2015; Vescovi et al., 2013; Hansen et al., 2013; Wessel et al., 2008). In one systematic review, 40% of the cases of MRONJ patients were under chemotherapy and 25% under corticosteroids, whereas 15% of the cases of MRONJ appeared spontaneously (Fliefel et al., 2015). In the present study one of the patients was under long term treatment with chemotherapy due to a breast cancer. Moreover, other studies found a relation of higher incidence of MRONJ in females, smokers, people with obesity and increased age group (68.9 years) (Katz and Ordoveza, 2014; Vidal-Real et al., 2015). Two of the subjects treated in the present study were heavy smokers (more than 20 cigarettes/day) and the mean age of the three female subjects was 69.3 years. It was reported that dental extractions, periodontitis and dental caries are risk factors related with the onset of MRONJ (Marx et al., 2005; Abu-Id et al., 2008). Other procedures such as periodontal surgery, apicoectomy and dental implant surgery have been related to higher risk of developing MRONJ (Katz and Ordoveza, 2014). One systematic review reported that 62% of the patients that developed MRONJ, had received an extraction before, which is in accordance with the present study (66%) (Fliefel et al., 2015). Bacteria may also be a co-factor in the pathogenesis of ONJ. Some studies found that bacteria related with ONJ are different from the flora found in control subjects. Colonies of Actinomyces and inflammatory cell infiltrates have been described histologically in biopsies obtained from necrotic bone in areas of ONJ, but the clinical significance of this observation has not been established (Ruggiero et al., 2014; Marx et al., 2005; Abu-Id et al., 2008; Ficarra et al., 2005; Lee et al., 2007a; Dimitrakopoulos et al., 2006). Actinomycosis develops when Actinomyces bacteria colonize tissues with poor blood supply.

Although it normally affects soft tissues, it can spread to the bone in 15% of the cases (Lee et al., 2007a). In all the patients of the present study, Actinomyces were identified histologically, but it cannot be concluded if these represent a surface contaminant or if it is related to the development of ONJ.

Due to the infection that affects hypovascular and necrotic tissue, antibiotics were prescribed for at least 10 days until the lesion was completely healed and no exposed bone was present. This poor irrigated area prevents proper penetration of antibiotics into the infected zone (Lee et al., 2007a).

The treatment of ONJ is under big debate. Studies reported both surgical and non-surgical conservative treatments. Systematic reviews reported a better outcome when surgical debridement of the osteonecrotic lesions was performed (74–85% success rate) (Rupel et al., 2014; Kuhl et al., 2012). Whereas when conservative non-surgical treatment with oral disinfectants and antibiotics was applied, the success rate was only 36–38.5% (Abu-Id et al., 2008; Rupel et al., 2014). In the present study, surgical necrotic bone debridement and attempt to soft tissue closure were performed. All the cases were successful with soft tissue closure and with no symptoms or signs of necrosis or infection, which is in accordance with other studies that reported 86% success when surgical debridement was performed (Abu-Id et al., 2008).

Autologous growth factors have also been used as an adjunctive therapy to fill the defects left after surgical necrotic bone and tissue debridement, to enhance new bone and soft tissue formation (Mozzati et al., 2012a; Lee et al., 2007b; Curi et al., 2007). PRGF is an autologous concentration of human platelets obtained by centrifuged blood. When the platelets are activated, they release protein growth factors such as platelet derived growth factor, vascular endothelial growth factor, transforming growth factor beta and epidermal growth factor that accelerate the healing process and induce an optimal cellular response. Among the growth factors, PRGF, has demonstrated the potential to influence bone regeneration and promote osteogenic differentiation in a wide number of surgical applications in the oral field (Pardinas Lopez et al., 2015; Del Fabbro et al., 2015; Adornato et al., 2007; Martins et al., 2012; Anitua et al., 2013; Khoully et al., 2017; Anitua et al., 2009; Del Fabbro et al., 2013; Anitua et al., 2015). Moreover, it has been reported that PRGF acts as a cytoprotector against the toxic effect of bisphosphonates on fibroblasts and osteoblasts (Anitua et al., 2016).

Osteonecrosis is a condition where biological disruption occurs, so growth factors may provide a beneficial effect accelerating bone and soft tissue healing after surgical debridement of necrotic bone, and for preventing the onset of MRONJ in patients under anti-resorptive drugs treatment submitted to surgical procedures (Adornato et al., 2007; Lopez-Jornet et al., 2016). Moreover, due to the presence of Actinomyces in most of the cases of MRONJ, the antibacterial properties of PRGF may play an important role in the treatment of the infection and resolution of the pathology (Anitua et al., 2012; Fabbro et al., 2016). Three systematic reviews reported an 81.5–92% satisfactory healing when autologous growth factors were used in combination with surgical debridement of the necrotic area. These values are slightly higher compared to those where other surgical procedures without using growth factors were performed (74–85%), although differences were not statistically significant (Del Fabbro et al., 2015; Fliefel et al., 2015; Lopez-Jornet et al., 2016). In our study 100% of the cases had a satisfactory healing, which is in accordance with the current literature.

Different articles have proposed that treatment of MRONJ with growth factors may promote bone regeneration, although no article has reported measures of the amount of bone regenerated yet (Mozzati et al., 2012a; Adornato et al., 2007; Lee et al., 2007b). One study reported radiographically bone regeneration after treating 32 MRONJ cases with PRGF, but no quantification was made (Mozzati et al., 2012a). For our study, a volumetric analysis was performed to measure bone changes occurred from the pre-surgical stage to 12 months after treatment was finished. This analysis uses CBCT files that are converted into STL files which can be analyzed volumetrically using a 3D

software. Several studies have used the CBCT for volumetrically assess bone changes after different surgical procedures (Froum et al., 2014; Alayan and Ivanovski, 2017).

However, to our knowledge, the present study is the first to measure bone volume changes after surgically treating MRONJ.

The mechanism of action of platelet-rich plasma on peripheral nerve regeneration is currently under study, and recent studies in animals have reported positive effects on regeneration of peripheral nerves (Yu et al., 2011). Two of the patients in the present study presented inferior alveolar nerve affection that recovered after treatment. One similar case presenting MRONJ and hemimandibular paresthesia has been published in the literature. Surgical debridement of necrotic bone and the application of PRGF was performed. One year after treatment the sensitivity was totally recovered (Anitua et al., 2013). The results in the present study throw another promising proof that autologous growth factors may influence nerve recovery.

One of the limitations of the present study is that only 3 patients were treated using this protocol. Moreover, the patients were under different types of medications and had different medical history which may have an influence on the treatment outcome. Another limitation is that there was no control group/site to confirm the efficacy of the PRGF therapy. Also, bone changes and possible bone regeneration in the treated areas could not be verified with histological analysis due to obvious ethical reasons.

## 5. Conclusions

All patients in the present study were surgically treated debriding necrotic bone and using PRGF, achieving a 100% success in a follow up of 30 months. Bone healing with increase of bone volume was found in all cases. The use of PRGF as an adjunct therapy to oral surgery procedures may be an effective protocol in controlling and treating MRONJ. Further studies involving randomized clinical studies and larger cohort of patients including bone volume analysis are necessary to confirm these results.

## Conflicts of interest

The authors of this article claim to have no financial interest, either directly or indirectly, in the products or information listed in the article.

## Transparency document

The Transparency document associated with this article can be found, in online version.

## References

Abu-Id, M.H., Warnke, P.H., Gottschalk, J., Springer, I., Wiltfang, J., Acil, Y., et al., 2008. "Bis-phoshy jaws" - high and low risk factors for bisphosphonate-induced osteonecrosis of the jaw. *J. Craniomaxillofac. Surg.* 36 (2), 95–103.

Adornato, M.C., Morcos, I., Rozanski, J., 2007. The treatment of bisphosphonate-associated osteonecrosis of the jaws with bone resection and autologous platelet-derived growth factors. *J. Am. Dent. Assoc.* 138 (7), 971–977.

Alayan, J., Ivanovski, S., 2017. A prospective controlled trial comparing xenograft/autogenous bone and collagen-stabilized xenograft for maxillary sinus augmentation-complications, patient-reported outcomes and volumetric analysis. *Clin. Oral Implants Res.* 29 (2), 248–262.

Anitua, E., Prado, R., Orive, G., 2009. A lateral approach for sinus elevation using PRGF technology. *Clin. Implant. Dent. Relat. Res.* 11 (Suppl. 1), e23–e31.

Anitua, E., Alonso, R., Girbau, C., Aguirre, J.J., Muruzabal, F., Orive, G., 2012. Antibacterial effect of plasma rich in growth factors (PRGF(R)-Endoret(R)) against *Staphylococcus aureus* and *Staphylococcus epidermidis* strains. *Clin. Exp. Dermatol.* 37 (6), 652–657.

Anitua, E., Begona, L., Orive, G., 2013. Treatment of hemimandibular paresthesia in a patient with bisphosphonate-related osteonecrosis of the jaw (BRONJ) by combining surgical resection and PRGF-Endoret. *Br. J. Oral Maxillofac. Surg.* 51 (8), e272–e274.

Anitua, E., Murias-Freijo, A., Alkhraisat, M.H., Orive, G., 2015. Clinical, radiographical, and histological outcomes of plasma rich in growth factors in extraction socket: a randomized controlled clinical trial. *Clin. Oral Investig.* 19 (3), 589–600.

Anitua, E., Zalduendo, M., Troya, M., Orive, G., 2016. PRGF exerts a cytoprotective role in

zoledronic acid-treated oral cells. *Clin. Oral Investig.* 20 (3), 513–521.

Bhat, P., Cariappa, K.M., 2012. Inferior alveolar nerve deficits and recovery following surgical removal of impacted mandibular third molars. *J. Maxillofac. Oral Surg.* 11 (3), 304–308.

Curi, M.M., Cossolin, G.S., Koga, D.H., Araujo, S.R., Feher, O., dos Santos, M.O., et al., 2007. Treatment of avascular osteonecrosis of the mandible in cancer patients with a history of bisphosphonate therapy by combining bone resection and autologous platelet-rich plasma: report of 3 cases. *Journal of oral and maxillofacial surgery: official journal of the American Association of Oral and Maxillofacial Surgeons* 65 (2), 349–355.

Del Fabbro, M., Bortolin, M., Taschieri, S., Weinstein, R.L., 2013. Effect of autologous growth factors in maxillary sinus augmentation: a systematic review. *Clin. Implant. Dent. Relat. Res.* 15 (2), 205–216.

Del Fabbro, M., Corbella, S., Taschieri, S., Francetti, L., Weinstein, R., 2014. Autologous platelet concentrate for post-extraction socket healing: a systematic review. *European journal of oral implantology* 7 (4), 333–344.

Del Fabbro, M., Galesio, G., Mozzati, M., 2015. Autologous platelet concentrates for bisphosphonate-related osteonecrosis of the jaw treatment and prevention. A systematic review of the literature. *Eur. J. Cancer* 51 (1), 62–74.

Dimitrakopoulos, I., Magopoulos, C., Karakasis, D., 2006. Bisphosphonate-induced avascular osteonecrosis of the jaws: a clinical report of 11 cases. *Int. J. Oral Maxillofac. Surg.* 35 (7), 588–593.

Fabbro, M.D., Bortolin, M., Taschieri, S., Ceci, C., Weinstein, R.L., 2016. Antimicrobial properties of platelet-rich preparations. A systematic review of the current pre-clinical evidence. *Platelets* 27 (4), 276–285.

Ficarra, G., Beninati, F., Rubino, I., Vannucchi, A., Longo, G., Tonelli, P., et al., 2005. Osteonecrosis of the jaws in periodontal patients with a history of bisphosphonates treatment. *J. Clin. Periodontol.* 32 (11), 1123–1128.

Fliefel, R., Troltschke, M., Kuhnisch, J., Ehrenfeld, M., Otto, S., 2015. Treatment strategies and outcomes of bisphosphonate-related osteonecrosis of the jaw (BRONJ) with characterization of patients: a systematic review. *Int. J. Oral Maxillofac. Surg.* 44 (5), 568–585.

Froum, S.J., Wallace, S., Cho, S.C., Khoully, I., Rosenberg, E., Corby, P., et al., 2014. Radiographic comparison of different concentrations of recombinant human bone morphogenetic protein with allogenic bone compared with the use of 100% mineralized cancellous bone allograft in maxillary sinus grafting. *The International journal of periodontics & restorative dentistry* 34 (5), 611–620.

Gagnier, J.J., Kienle, G., Altman, D.G., Moher, D., Sox, H., Riley, D., et al., 2013. The CARE guidelines: consensus-based clinical case reporting guideline development. *Glob Adv Health Med* 2 (5), 38–43.

Gallego, L., Junquera, L., Pelaz, A., Hernandez, J., Megias, J., 2012. The use of pedicled buccal fat pad combined with sequestrectomy in bisphosphonate-related osteonecrosis of the maxilla. *Medicina oral, patologia oral y cirugía bucal* 17 (2), e236–e241.

Hansen, P.J., Knitschke, M., Draenert, F.G., Irle, S., Neff, A., 2013. Incidence of bisphosphonate-related osteonecrosis of the jaws (BRONJ) in patients taking bisphosphonates for osteoporosis treatment - a grossly underestimated risk? *Clin. Oral Investig.* 17 (8), 1829–1837.

Katz, J., Ordoeza, P.A., 2014. Bisphosphonate-related osteonecrosis of the jaw (BRONJ) associated with a once-yearly IV infusion of zoledronic acid (Reclast) 5 mg: two cases and review of the literature. *Quintessence Int.* 45 (8), 685–690.

Khoully, I., Pardiñas López, S., Aliaga, I., Froum, S.J., 2017. Long-term implant survival after 100 maxillary sinus augmentations using plasma rich in growth factors. *Implant. Dent.* 26 (2), 199–208.

Kim, K.M., Rhee, Y., Kwon, Y.D., Kwon, T.G., Lee, J.K., Kim, D.Y., 2015. Medication related osteonecrosis of the jaw: 2015 position statement of the Korean Society for bone and mineral research and the Korean association of oral and maxillofacial surgeons. *Journal of bone metabolism* 22 (4), 151–165.

Kuhl, S., Walter, C., Acham, S., Pfeffer, R., Lambrecht, J.T., 2012. Bisphosphonate-related osteonecrosis of the jaws—a review. *Oral Oncol.* 48 (10), 938–947.

Cameron Y. S. Lee D, MD; Teresa David, DO; Michael Nishime, DDS. Use of platelet-rich plasma in the management of oral bisphosphonate associated osteonecrosis of the jaw: a report of 2 cases. *Journal of Oral Implantology.* 2007a;Vol. XXXIII(No. Six).

Lee, C.Y., David, T., Nishime, M., 2007b. Use of platelet-rich plasma in the management of oral bisphosphonate-associated osteonecrosis of the jaw: a report of 2 cases. *The Journal of oral implantology* 33 (6), 371–382.

Lopez-Jornet, P., Sanchez Perez, A., Amaral Mendes, R., Tobias, A., 2016. Medication-related osteonecrosis of the jaw: is autologous platelet concentrate application effective for prevention and treatment? A systematic review. *Journal of cranio-maxillofacial surgery: official publication of the European Association for Cranio-Maxillofacial Surgery* 44 (8), 1067–1072.

Martins, M.A., Martins, M.D., Lascala, C.A., Curi, M.M., Migliorati, C.A., Tennis, C.A., et al., 2012. Association of laser phototherapy with PRP improves healing of bisphosphonate-related osteonecrosis of the jaws in cancer patients: a preliminary study. *Oral Oncol.* 48 (1), 79–84.

Marx, R.E., Carlson, E.R., Eichstaedt, R.M., Schimmele, S.R., Strauss, J.E., Georgeff, K.R., 1998. Platelet-rich plasma: growth factor enhancement for bone grafts. *Oral surgery, oral medicine, oral pathology, oral radiology, and endodontics* 85 (6), 638–646.

Marx, R.E., Sawatari, Y., Fortin, M., Broumand, V., 2005. Bisphosphonate-induced exposed bone (osteonecrosis/osteopetrosis) of the jaws: risk factors, recognition, prevention, and treatment. *Journal of oral and maxillofacial surgery: official journal of the American Association of Oral and Maxillofacial Surgeons* 63 (11), 1567–1575.

Mozzati, M., Galesio, G., Arata, V., Pol, R., Scoletta, M., 2012a. Platelet-rich therapies in the treatment of intravenous bisphosphonate-related osteonecrosis of the jaw: a report of 32 cases. *Oral Oncol.* 48 (5), 469–474.

Mozzati, M., Arata, V., Galesio, G., 2012b. Tooth extraction in patients on zoledronic acid therapy. *Oral Oncol.* 48 (9), 817–821.

- Pardinas Lopez, S., Froum, S., Khouly, I., 2015. Histomorphometric analysis of a biopsy harvested 10 years after maxillary sinus augmentation with anorganic bovine bone matrix and plasma rich in growth factors: a case report. *Implant. Dent.* 24 (4), 480–486.
- Pelaz, A., Junquera, L., Gallego, L., Garcia-Consuegra, L., Junquera, S., Gomez, C., 2014. Alternative treatments for oral bisphosphonate-related osteonecrosis of the jaws: a pilot study comparing fibrin rich in growth factors and teriparatide. *Medicina Oral Patología Oral y Cirugía Bucal.* e320–e326.
- Ruggiero, S.L., 2013. Emerging concepts in the management and treatment of osteonecrosis of the jaw. *Oral and maxillofacial surgery clinics of North America* 25 (1), 11–20.
- Ruggiero, S.L., Fantasia, J., Carlson, E., 2006. Bisphosphonate-related osteonecrosis of the jaw: background and guidelines for diagnosis, staging and management. *Oral surgery, oral medicine, oral pathology, oral radiology, and endodontics* 102 (4), 433–441.
- Ruggiero, S.L., Dodson, T.B., Fantasia, J., Goodday, R., Aghaloo, T., Mehrotra, B., et al., 2014. American Association of Oral and Maxillofacial Surgeons position paper on medication-related osteonecrosis of the jaw—2014 update. *Journal of oral and maxillofacial surgery: official journal of the American Association of Oral and Maxillofacial Surgeons* 72 (10), 1938–1956.
- Rupel, K., Ottaviani, G., Gobbo, M., Contardo, L., Tirelli, G., Vescovi, P., et al., 2014. A systematic review of therapeutical approaches in bisphosphonates-related osteonecrosis of the jaw (BRONJ). *Oral Oncol.* 50 (11), 1049–1057.
- Scoletta, M., Arata, V., Arduino, P.G., Lerda, E., Chiecchio, A., Galesio, G., et al., 2013. Tooth extractions in intravenous bisphosphonate-treated patients: a refined protocol. *Journal of oral and maxillofacial surgery: official journal of the American Association of Oral and Maxillofacial Surgeons* 71 (6), 994–999.
- Vescovi, P., Manfredi, M., Merigo, E., Meleti, M., Fornaini, C., Rocca, J.P., et al., 2010. Surgical approach with Er:YAG laser on osteonecrosis of the jaws (ONJ) in patients under bisphosphonate therapy (BPT). *Lasers Med. Sci.* 25 (1), 101–113.
- Vescovi, P., Meleti, M., Merigo, E., Manfredi, M., Fornaini, C., Guidotti, R., et al., 2013. Case series of 589 tooth extractions in patients under bisphosphonates therapy. Proposal of a clinical protocol supported by Nd:YAG low-level laser therapy. *Medicina oral, patologia oral y cirugía bucal* 18 (4), e680–e685.
- Vidal-Real, C., Perez-Sayans, M., Suarez-Penaranda, J.M., Gandara-Rey, J.M., Garcia-Garcia, A., 2015. Osteonecrosis of the Jaws in 194 Patients Who Have Undergone Intravenous Bisphosphonate Therapy in Spain. *Medicina Oral Patología Oral y Cirugía Bucal*, pp. e267–e272.
- Wessel, J.H., Dodson, T.B., Zavras, A.I., 2008. Zoledronate, smoking, and obesity are strong risk factors for osteonecrosis of the jaw: a case-control study. *Journal of oral and maxillofacial surgery: official journal of the American Association of Oral and Maxillofacial Surgeons* 66 (4), 625–631.
- Yu, W., Wang, J., Yin, J., 2011. Platelet-rich plasma: a promising product for treatment of peripheral nerve regeneration after nerve injury. *Int J Neurosci* 121 (4), 176–180.
- Zuniga, J.R.E.G., 1992. A contemporary approach to the clinical evaluation of trigeminal nerve injuries. *Oral Maxillofac Clin North Am* 4 (2), 353–367.