

Hamstring Braid Graft Technique for Anterior Cruciate Ligament Reconstruction



Gonzalo Samitier, M.D., Ph.D., and Gustavo Vinagre, M.D., Ph.D.

Abstract: Hamstring autograft is one of the most used grafts for anterior cruciate ligament (ACL) reconstruction, although there are several graft preparation techniques. It is extremely difficult to mimic the biomechanical properties of the native ACL; thus, it is important to achieve a proper graft configuration, diameter, and length. To avoid reruptures, an optimal and reproducible hamstring autograft is desired. Hamstring autograft has been traditionally devalued when compared with other options such as bone–patellar tendon–bone autograft. The purpose of this Technical Note is to describe in detail a hamstring braid graft configuration that could potentially overcome the past disadvantages of ACL reconstruction.

The anterior cruciate ligament (ACL) lesion is one of the most common intra-articular injuries of the knee. Surgical reconstruction is the current standard of care for treatment of ACL tears, and it is one of the most challenging procedures in orthopaedic surgery.

Several factors play a crucial role in performing an adequate ACL reconstruction: tunnel positioning, graft selection, fixation, diameter, length, and configuration.¹⁻⁸

Graft selection continues to remain very controversial in ACL reconstruction.⁹ It is an extremely important decision and should take into consideration different factors, such as surgeons' preference, patient needs/expectations, type and level of sports, and graft specifications.^{3,10-12}

The hamstring autograft is a commonly used graft due to some positive benefits, such as accessibility and ease of harvest, soft tissue tunnel passage, comparable strength to native ACL, and a custom individualized

graft length and diameter.^{1,3,5,6,7} Most of the advantages of using hamstring autograft are the disadvantages of using bone–patellar tendon–bone (BPTB) autograft, such as anterior knee pain, risk of patellar fracture, patellar tendinitis/tendon avulsion or rupture/condropathy, patella baja, tibial fracture, loss of extension, or pediatric ACL reconstruction (contra-indicated to use bone plugs in open physis).^{3,13-18}

BPTB autograft remains the gold standard for ACL reconstruction in young, active, and high-demand athletes. Recent studies have shown that BPTB autograft has a lower rerupture rate and is more objectively stable when compared with hamstring autograft.^{19,20} Nevertheless, different studies have shown clinical results to be equivalent between semitendinosus-gracilis tendons autograft and BPTB autograft in ACL reconstruction.^{4,20-23}

There are several graft preparation techniques for hamstring autograft with different final diameters, lengths, and configurations.^{3-5,7,8} To obtain an optimal ACL graft it must have a strength that is similar to or exceeds the native ACL.

The purpose of this Technical Note is to describe in detail the hamstring braid graft (Table 1), which is an easy-to-prepare and reproducible graft with theoretically similar biomechanical properties to the native ACL tissue for ACL reconstruction.

Surgical Technique

Graft Harvest

For hamstring braid graft, both semitendinosus (ST) and gracilis (GC) tendons should be harvested. An oblique incision is made medial to the tibial tubercle to

From the Department of Orthopaedic Surgery and Traumatology, Hospital General de Villalba (G.S.), Madrid; and Department of Orthopaedic Surgery and Traumatology, Hospital de Verín (G.V.), Galicia, Spain.

The authors report the following potential conflicts of interest or sources of funding: G.S. receives support from Smith & Nephew, DePuy, Johnson & Johnson, and Lima. Full ICMJE author disclosure forms are available for this article online, as supplementary material.

Received January 19, 2019; accepted March 19, 2019.

Address correspondence to Gustavo Vinagre, M.D., Ph.D., Department of Orthopaedic Surgery and Traumatology, Hospital de Verín, Av. de Laza, 0, 32600 Verín, Ourense, Spain. E-mail: gustavovinagre@gustavovinagre.com

© 2019 by the Arthroscopy Association of North America. Published by Elsevier. This is an open access article under the CC BY-NC-ND license (<http://creativecommons.org/licenses/by-nc-nd/4.0/>).

2212-6287/1980

<https://doi.org/10.1016/j.eats.2019.03.022>

Table 1. Advantages and Disadvantages of the Hamstring Braid Graft Configuration for Anterior Cruciate Ligament (ACL) Reconstruction of the Knee

Advantages	Disadvantages
<ul style="list-style-type: none"> • Thicker graft (approximately 1 mm diameter increase). • Ribbon-like and braided shape, mimicking the ACL native shape and theoretically increasing biomechanical strength. • Does not require the mastering of different hamstring preparation techniques to increase graft diameter. • Stronger tibial fixation (4 strands in contact with tibial tunnel and interference screw), potentially decreasing graft rupture during screw insertion or over time. • Can be used with fixed or adjustable cortical loop suspensory devices. • The braid can be made with 3 ends (instead of 4), in case there is rupture of one end during tendon harvesting. • Autograft or allograft of other tendon types can be used to configure the braid. • This technique can be used for ACL or posterior cruciate ligament reconstruction. • Reproducible final graft. 	<ul style="list-style-type: none"> • Shortening of approximately 5-10 mm in length.

reach the sartorius fascia and pes anserine bursa and is approximately 2.5 cm in length. An oblique incision in the sartorius fascia is then made to expose the hamstring tendons. Once the tendons are identified and released from the surrounding attachments, an open tendon stripper is used to release each tendon from its proximal muscular attachment while flexing the knee in a slight varus motion. Each tendon is then released distally in the tibial tubercle.




Figure 1. Initial hamstring graft preparation using semitendinosus and gracilis autologous tendons. First, each of the 4 free ends are stitched with a nonabsorbable suture (white arrow). Then the 2 hamstring tendons are folded in half, passing both of them through the cortical suspensory adjustable-length device loop; then the 4 ends of the graft are stitched together 1 cm distally (yellow arrow) from the cortical suspensory adjustable-length device loop (blue arrow) to keep the same length of each strand of the graft when preparing the braid configuration (the same length of semitendinosus free ends and same length of gracilis free ends must be kept).

Graft Preparation

This technique was developed by the senior author (G.S.); the graft preparation and configuration are done in a graft preparation station (Smith & Nephew, Andover, MA; [Video 1](#)). The removal of the muscular tissue of each tendon is then performed using scissors or scalpel. Unstable portions of each tendon are also removed. Both tendons are then loaded in a cortical suspensory adjustable-length device (Ultrabutton, Smith & Nephew) to create a 4-strand graft with 2 tendons (GC and ST). The 4 free ends are stitched with a nonabsorbable suture (e.g., Ethibond Excel No. 2, Ethicon), and the 4-strand graft is stitched together 1 cm distally from the cortical suspensory adjustable-length device to reinforce and keep the same length to each free end of each tendon (same length to ST free ends and same length to GC free ends; [Fig 1](#)). Each end of the graft should be grabbed with a hand with some tension and divergence with the help of 1 or 2 assistants (ideally). Proper measurements (diameter and length) are made before and after preparing the hamstring braid graft configuration.

Graft Configuration

Hamstring Braid Graft Preparation

Starting right to left, the distal end of the graft that is more on the right should be passed above the distal end on its left ([Fig 2](#), panel 1), then below the next end on the left ([Fig 2](#), panel 2), and finally above to the last of the 4 ends ([Fig 2](#), panel 3), which initially was located on the left corner ([Fig 2](#); [Video 1](#)). This sequence must be repeated until no more distally remaining tendon is available. At the end of the hamstring braid graft configuration, each suture pair (same tendon) should be hand stitched together; then unstable portions of the graft are removed and final measurements can be made.

Other pearls and pitfalls should be taken into account in the surgical graft preparation technique for obtaining an optimal hamstring braid graft ([Table 2](#)).

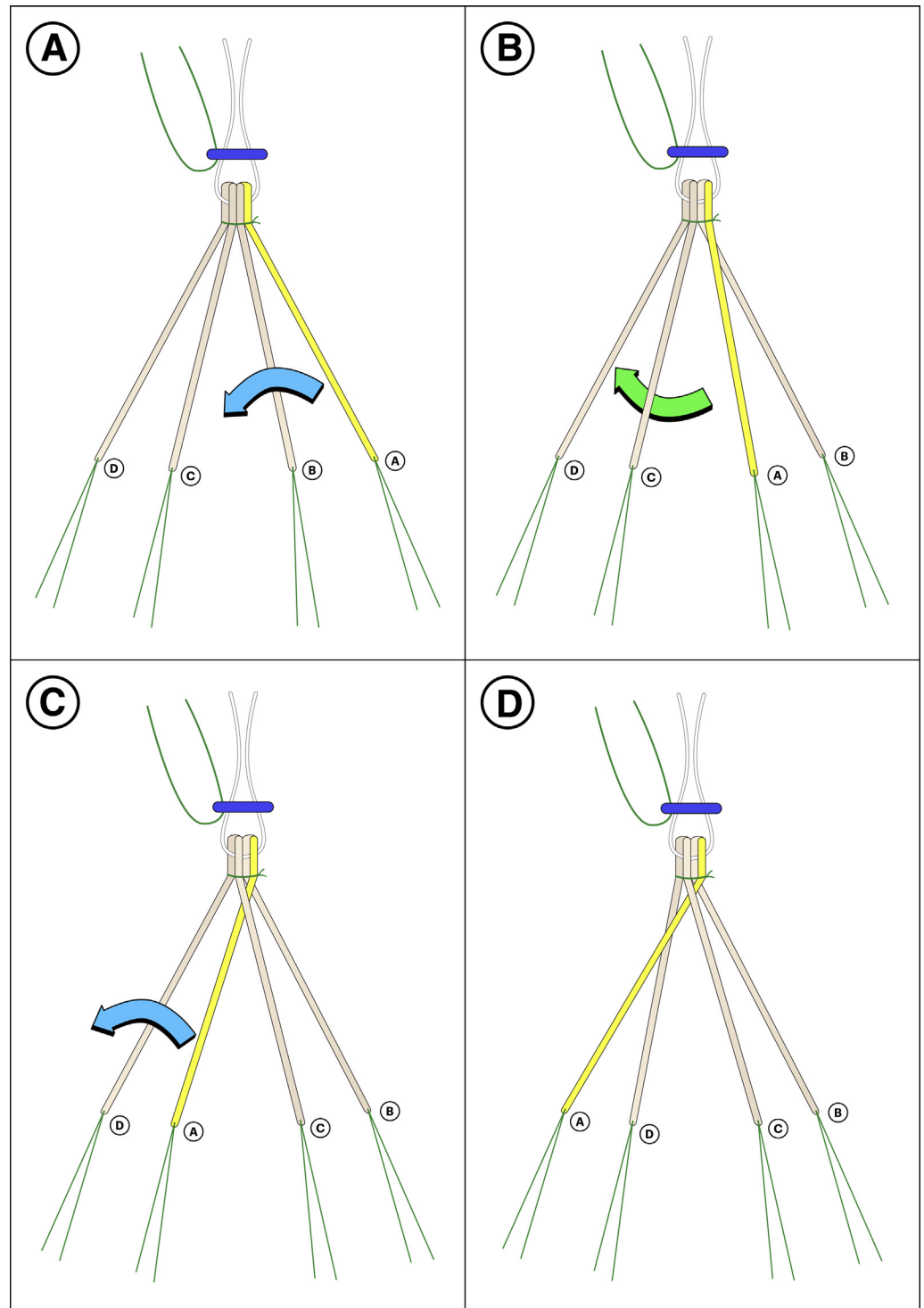


Fig 2. The 4-step sequence to recreate the braided configuration of a hamstring graft used for anterior cruciate ligament reconstruction. Starting right to left, the distal end of the graft more on the right (A, yellow) should be passed above the distal end on its left (B), then below the next end on the left (C), and finally above to last end (D), which initially was located on the left corner. This sequence must be repeated until no more distally remaining tendon is available. At the end of the hamstring braid graft configuration, each suture pair (same tendon) should be hand stitched together.

Graft Passage and Fixation

The final graft should have a “ribbon-like” appearance as described by Śmigielski et al.,²⁴ with a braid appearance as well (Fig 3). Care should be taken to push the final graft into both tunnels and keep it tensioned (Fig 4). Interference screw should be placed medial to the graft in

the tibia, with the end tip close to the articular entry level to avoid extra-articular migration of the synovial fluid and to minimize osteolysis related to the windshield wiper effect. With this ribbon-like flattened braid graft configuration, the 4 strands of the graft are uniformly compressed by the interference screw.

Table 2. Pearls and Pitfalls of the Hamstring Braid Graft Preparation Technique for Anterior Cruciate Ligament Reconstruction

Pearls	Pitfalls
<ul style="list-style-type: none"> • The 4 free ends should be stitched with a nonabsorbable suture, and the 4-strand graft should be stitched together 1 cm distally from the cortical suspensory device. • After finishing the braid, the free ends should be sutured to each other to keep the braid configuration stable. • Use a graft station with measurements and a proper tension mechanism for graft pretensioning. 	<ul style="list-style-type: none"> • Place the cortical suspensory device before starting the braid configuration. • Improper continuous tension and angles during braid preparation can lead to nonuniform final graft configuration. • A minimum of 8-9 cm in length is desirable for final graft safe fixation. • Be careful when cutting the suspensory device sutures after femoral and tibial fixation to avoid flipping the device.

Discussion

Numerous different hamstring autograft preparation techniques have been described in the literature regarding different configurations.^{3,4,5,7,8}

Different studies have compared BTPB versus hamstring autograft.^{4,9,20-23} Some studies have shown equivalence between BTPB and ST-GC autografts in ACL reconstruction.^{4,20-23} Xie et al.²⁰ have shown the superiority of BTPB autograft in rotation stability when compared with 4-strand hamstring tendon autografts.

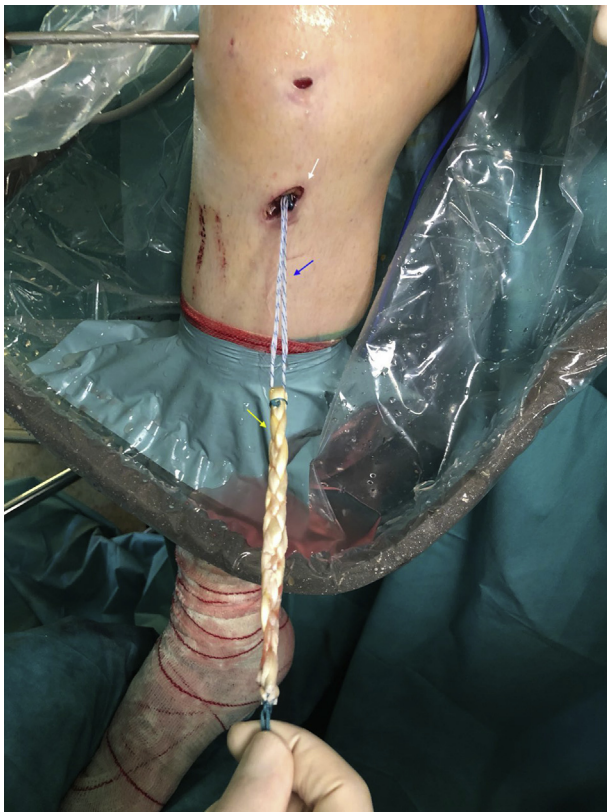

Fig 3. Photograph from the outside during anterior cruciate ligament reconstruction when the graft is about to enter through the tibial tunnel in the anteromedial aspect of the proximal leg, medial to the tibial tuberosity (white arrow); the patient is supine, and the right leg is hanging with 90° of flexion; the braided ribbon-like appearance of the final graft is apparent (yellow arrow), held with the cortical suspensory adjustable-length device loop (blue arrow).

Samuelsen et al.'s⁹ meta-analysis of 47,613 patients comparing hamstring autograft versus BPTB reported that hamstring autografts failed at a higher rate than BPTB autograft. However, Dai et al.⁴ have shown superior anteroposterior and stability of 6-strand hamstring allograft versus BPTB allograft. This finding reinforces our hypothesis that a stronger and more robust hamstring graft configuration will lead to a better stability and potentially better functional results.

The comparison of BTPB autograft, a much more standardized and reproducible final graft after its preparation, to different types of hamstring autografts (with different diameters, lengths, and configurations) makes this comparison unfair and unequal.

According to Conte et al.,¹ the size of hamstring autograft matters. A graft <8 mm in diameter is a risk factor for poor outcomes with an increase in failure rates. Thus, it is essential to master different hamstring graft preparation techniques to obtain an individualized graft with the appropriate diameter and length that matches the patient's anatomy, height, and physical demand.

The presumed advantages of performing the hamstring braid graft technique (Table 1) are obtaining a thicker graft (approximately 1 mm higher, despite having a shortening of approximately 5-10 mm in length); having an even ribbon-like graft, which seems to reproduce the native

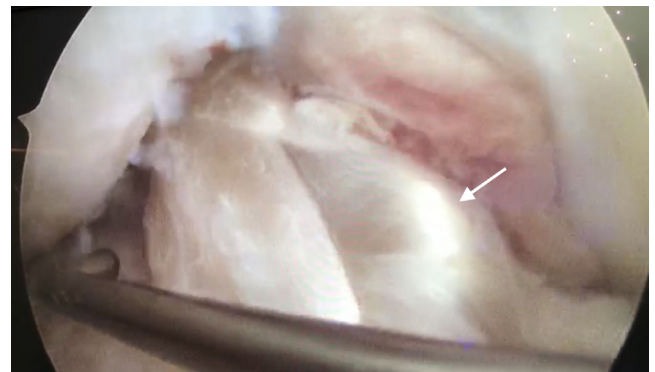


Fig 4. Arthroscopic intra-articular view (right knee, 90° flexion) of the final anterior cruciate ligament graft once it is stabilized; the view is from the anterolateral portal, and the probe is handled from the anteromedial accessory portal; the hamstring braid configuration can be observed inside the trochlear notch placed anatomically (white arrow).

ACL shape²⁴; and having a braid-shaped graft, which could mimic the mechanical behavior of the native ACL (in vivo studies should be performed to prove its strength). Folding the tendons more than once is not required, nor mastering different hamstring configuration techniques that fold the graft in different strands to obtain a much more reproducible final graft. This configuration allows a uniform fixation of the 4 strands of the graft with the interference screw, which leads to a stronger tibial fixation, minimizing the incidence of “cutting through” and reducing the potential need for double tibial fixation. This configuration can be used for posterior cruciate ligament (PCL) reconstruction. In addition, this braided configuration can theoretically compensate for the intrinsic viscoelasticity related to soft tissue grafts, minimizing the stretching after the reconstruction that eventually ends in laxity and reruptures.

We also considered the potential additional risks and/or limitations of this technique for our patients before applying it. One of the main potential limitations is that the graft after the creation of the braid will be shortened by approximately 5 to 10 mm; although this is a problem particularly in hamstring ACL reconstruction, it can also be a problem in the case of very short tendons, large-size patients, or when performing a PCL reconstruction where a minimum 9 mm graft is desirable. In these cases we simply recommend not making the braid configuration to maintain the longest graft possible.

Another potential limitation of our work is the lack of biomechanical results to corroborate our clinical observations; the presumed increased strength and resistance of our braided thicker graft could have an opposite effect to the one desired and turn it too rigid, and therefore cause an augmented risk of rerupture in the mid-long term; although we have not observed this effect in our patients, long-term prospective clinical evaluation is necessary to elucidate whether clinical results in terms of stability and graft duration are effectively improved or not using this graft configuration.

Finally, it is necessary to take into account that a minimum of training is needed to prepare the graft, which also will take a few extra minutes if the surgeon has to prepare it him- or herself; this must be taken into account for the total duration of the intervention.

In conclusion, the hamstring braid graft is a reliable, easy-to-prepare, and reproducible graft configuration that provides a stronger and more uniform hamstring graft than can be used in primary and revision ACL/PCL reconstruction and should be in the armamentarium of every ACL orthopaedic sports knee surgeon.

Acknowledgments

The authors thank Maria Sava, College of Osteopathic Medicine of the Pacific Western University of Health Sciences, for the English correction of this manuscript.

References

- Conte EJ, Hyatt AE, Gatt CJ Jr, Dhawan A. Hamstring autograft size can be predicted and is a potential risk factor for anterior cruciate ligament reconstruction failure. *Arthroscopy* 2014;30:882-890.
- Iriuchishima T, Shirakura K, Yorifuji H, Aizawa S, Fu FH. Size comparison of ACL footprint and reconstructed autograft. *Knee Surg Sports Traumatol Arthrosc* 2013;21:797-803.
- Vinagre G, Kennedy NI, Chahla J, et al. Hamstring graft preparation techniques for anterior cruciate ligament reconstruction. *Arthrosc Tech* 2017;6:e2079-e2084.
- Dai C, Wang F, Wang X, Wang R, Wang S, Tang S. Arthroscopic single-bundle anterior cruciate ligament reconstruction with six-strand hamstring tendon allograft versus bone-patellar tendon-bone allograft. *Knee Surg Sports Traumatol Arthrosc* 2016;24:2915-2922.
- Calvo R, Figueroa D, Figueroa F, et al. Five-strand hamstring autograft versus quadruple hamstring autograft with graft diameters 8.0 millimeters or more in anterior cruciate ligament reconstruction: Clinical outcomes with a minimum 2-year follow-up. *Arthroscopy* 2017;33:1007-1013.
- Fabbri M, Monaco E, Lanzetti RM, et al. Single harvesting in the all-inside graft-link technique: Is the graft length crucial for success? A biomechanical study. *J Orthop Traumatol* 2017;18:17-22.
- Park K, Brusalis CM, Ganley TJ. The 8-strand hamstring autograft in anterior cruciate ligament reconstruction. *Arthrosc Tech* 2016;5:e1105-e1109.
- Lubowitz JH. All-inside anterior cruciate ligament graft link: Graft preparation technique. *Arthrosc Tech* 2012;1:e165-e168.
- Samuelsen BT, Webster KE, Johnson NR, Hewett TE, Krych AJ. Hamstring autograft versus patellar tendon autograft for ACL reconstruction: Is there a difference in graft failure rate? A meta-analysis of 47,613 patients. *Clin Orthop Rel Res* 2017;475:2459-2468.
- Duchman KR, Lynch TS, Spindler KP. Graft selection in anterior cruciate ligament surgery: Who gets what and why? *Clin Sports Med* 2017;36:25-33.
- Koh HS, In Y, Kong CG, Won HY, Kim KH, Lee JH. Factors affecting patients' graft choice in anterior cruciate ligament reconstruction. *Clin Orthop Surg* 2010;2:69-75.
- Struwer J, Ziring E, Oberkircher L, Schuttler KF, Efe T. Isolated anterior cruciate ligament reconstruction in patients aged fifty years: Comparison of hamstring graft versus bone-patellar tendon-bone graft. *Int Orthop* 2013;37:809-817.
- Poehling GG, Smith BP. Analysis of outcomes of anterior cruciate ligament repair with 5 year follow-up: Allograft versus autograft. *Arthroscopy* 2005;21:774-785.
- Sherman OH, Banffy MB. Anterior cruciate ligament reconstruction: Which graft is best? *Arthroscopy* 2004;2:974-980.
- Janson KA, Linko E, Sandelin J, Harilainen A. A prospective randomized study of patellar versus hamstring tendon autografts for anterior cruciate ligament reconstruction. *Am J Sports Med* 2003;31:12-18.
- Yasuda K, Tsujino J, Ohkoshi Y, Tanabe Y, Kaneda K. Graft site morbidity with autogenous semitendinosus and gracilis tendons. *Am J Sports Med* 1995;23:706-714.

17. Jin GK, Sang JY. The effects of hamstring harvesting on outcomes in anterior cruciate ligament reconstructed patients: A comparative study between hamstring- harvested and unharvested patients. *Arthroscopy* 2011;27:1226-1234.
18. Rosenburg TD, Franklin JL, Baldwin GN, Nelson KA. Extensor mechanism function after patellar tendon graft harvest for anterior cruciate ligament reconstruction. *Am J Sports Med* 1992;20:519-525.
19. Kim SJ, Choi CH, Kim SH, et al. Bone–patellar tendon–bone autograft could be recommended as a superior graft to hamstring autograft for ACL reconstruction in patients with generalized joint laxity: 2- and 5-year follow-up study. *Knee Surg Sports Traumatol Arthrosc* 2018;26:2568-2579.
20. Xie X, Liu X, Chen Z, Yu Y, Peng S, Li Q. A meta-analysis of bone-patellar tendon-bone autograft versus four-strand hamstring tendon autograft for anterior cruciate ligament reconstruction. *Knee* 2015;22:100-110.
21. Shaieb MD, Kan DM, Chang SK, Marumoto JM, Richardson AB. A prospective randomized comparison of patellar tendon versus semitendinosus and gracilis tendon autografts for anterior cruciate ligament reconstruction. *Am J Sports Med* 2002;30:214-220.
22. Spindler KP, Kuhn JE, Freedman KB, Matthews CE, Dittus RS, Harrell FE Jr. Anterior cruciate ligament reconstruction autograft choice: Bone-tendon-bone versus hamstring: Does it really matter? A systematic review. *Am J Sports Med* 2004;32:1986-1995.
23. Samuelsson K, Andersson D, Karlsson J. Treatment of anterior cruciate ligament injuries with special reference to graft type and surgical technique: An assessment of randomized controlled trials. *Arthroscopy* 2009;25:1139-1174.
24. Śmigielski R, Zdanowicz U, Drwięga M, Ciszek B, Ciszowska-Łysoń B, Siebold R. Ribbon like appearance of the mid-substance fibres of the anterior cruciate ligament close to its femoral insertion site: A cadaveric study including 111 knees. *Knee Surg Sports Traumatol Arthrosc* 2015;23:3143-3150.