

CASE REPORT

A 6q14.1-q15 microdeletion in a male patient with severe autistic disorder, lack of oral language, and dysmorphic features with concomitant presence of a maternally inherited Xp22.31 copy number gain

Ines Quintela¹, Montse Fernandez-Prieto², Lorena Gomez-Guerrero², Mariela Resches³, Jesus Eiris⁴, Francisco Barros² & Angel Carracedo^{1,2,5}

¹Grupo de Medicina Xenomica, Centro Nacional de Genotipado – Plataforma de Recursos Biomoleculares y Bioinformaticos – Instituto de Salud Carlos III (CeGen-PRB2-ISCIII), Universidade de Santiago de Compostela, Santiago de Compostela, Spain

²Grupo de Medicina Xenomica, CIBERER, Fundacion Publica Galega de Medicina Xenomica – SERGAS, Santiago de Compostela, Spain

³Departamento de Psicologia Evolutiva y de la Educacion, Universidade de Santiago de Compostela, Santiago de Compostela, Spain

⁴Unidad de Neurologia Pediatrica, Departamento de Pediatria, Hospital Clinico Universitario de Santiago de Compostela, Santiago de Compostela, Spain

⁵Center of Excellence in Genomic Medicine Research, King Abdulaziz University, Jeddah, Saudi Arabia

Correspondence

Francisco Barros, Fundacion Publica Galega de Medicina Xenomica, Edif. Consultas planta -2, Hospital Clinico Universitario, 15707 Santiago de Compostela, Spain. Tel: 34 981955188; Fax: 34 981 951473; E-mail: francisco.barros.anguera@sergas.es

Funding Information

No sources of funding were declared for this study.

Received: 15 January 2015; Accepted: 22 February 2015

Clinical Case Reports 2015; 3(6): 415–423

doi: 10.1002/ccr3.255

Introduction

In recent years, the use of Comparative Genomic Hybridization (CGH) and Single Nucleotide Polymorphism (SNP) arrays as the first genetic test for the diagnosis of neurodevelopmental disorders is enabling a genome-wide approach and the identification of new submicroscopic chromosomal abnormalities (namely Copy Number Variants or CNVs), undetectable by conventional techniques. Here, the molecular analysis using a high-resolution SNP array has allowed the identification of a rare heterozygous deletion of 4.96 Mb at 6q14.1-q15 and affecting 31 genes in a male patient with severe autistic disorder (AD), lack of oral language, and dysmorphic features. Interstitial deletions within the proximal region of the long arm of chromosome 6 are rare, variable in size, and location,

Key Clinical Message

We report on a male patient with severe autistic disorder, lack of oral language, and dysmorphic features who carries a rare interstitial microdeletion of 4.96 Mb at chromosome 6q14.1-q15. The patient also harbors a maternally inherited copy number gain of 1.69 Mb at chromosome Xp22.31, whose pathogenicity is under debate.

Keywords

6q14.1-q15 microdeletion, autistic disorder, intellectual disability, Xp22.31 gain.

involve different genes, have been implicated in developmental delay (DD), behavioral problems, autism (A), early-onset obesity, characteristic facial dysmorphism, and syndactyly of toes II/III, and are mainly de novo [1–5]. Coexisting in our patient, a subtelomeric maternally inherited copy-number gain of 1.69 Mb at Xp22.31 and encompassing six genes was also detected. Copy number gains at Xp22.31 are variable in size, location, and gene content, and they have been detected in patients with DD, intellectual disability (ID), A, seizures, dysmorphism, and/or multiple congenital anomalies (MCA). But since they have also been identified in healthy carrier parents and in controls, it has been proposed that these duplications are benign [6]. However, its potential pathogenicity is still under debate [7–15]. A plausible explanation for the incomplete penetrance and the phenotypic heterogeneity of these

chromosomal aberrations could be the coexistence of additional CNVs that might contribute to the patient's phenotypes [11]. So, a multiple-hit hypothesis, first proposed by Girirajan *et al.* [16] for the 16p12.1 microdeletions, could occur in our patient who, in addition to the Xp22.31 copy number gain, presents the 6q14.1-q15 microdeletion.

Here, we perform the clinical description and the molecular characterization of a male patient with a 6q14.1-q15 microdeletion. Furthermore, we review the previously reported patients with chromosomal CNVs in this region searching for plausible candidate genes. Alternatively, and taking into account that the pathogenicity of the Xp22.31 duplication is still unclear, the two-hit model is also discussed.

Materials and Methods

DNA samples from both the patient and his mother were obtained from peripheral blood and genotyped with the Affymetrix CytoScan High-Density SNP array and the Affymetrix CytoScan 750K SNP array (Affymetrix, Santa Clara, CA), respectively. The father's sample was not available for genetic analysis. Microarray-based copy number analysis was performed using the Chromosome Analysis Suite software version 1.2.2 (Affymetrix)

and the results were presented on the human genome assembly hg19 (Figs. 1 and 2).

Results

Clinical report

Our patient, an 8-year-old male, is the first child of a non-consanguineous couple of European descent. His family history is unremarkable, with the exception that his mother presented degenerative otosclerosis and required surgery on her right ear. The pregnancy was uneventful without remarkable prenatal data. Delivery was by cesarean section due to dystocia. Apgar scores were 8–10 at 1–5 min, respectively. His birth weight was 3080 g. Neonatal metabolic screening was normal. He presented scoliosis and mild hypospadias (surgery not required).

A neuropsychiatric clinical evaluation was performed at 2 years and 9 months. Weight: 12 kg (3rd–10th centile), height: 87.5 cm (3rd centile), head circumference: 49 cm (25th centile). Physical examination also showed a squared craniofacial profile, a wide forehead, sparse eyebrows in the outer portion, antimongoloid palpebral slant, a long, and prominent philtrum, micrognathia, a depressed nasal bridge, a thin upper lip, and large ears.

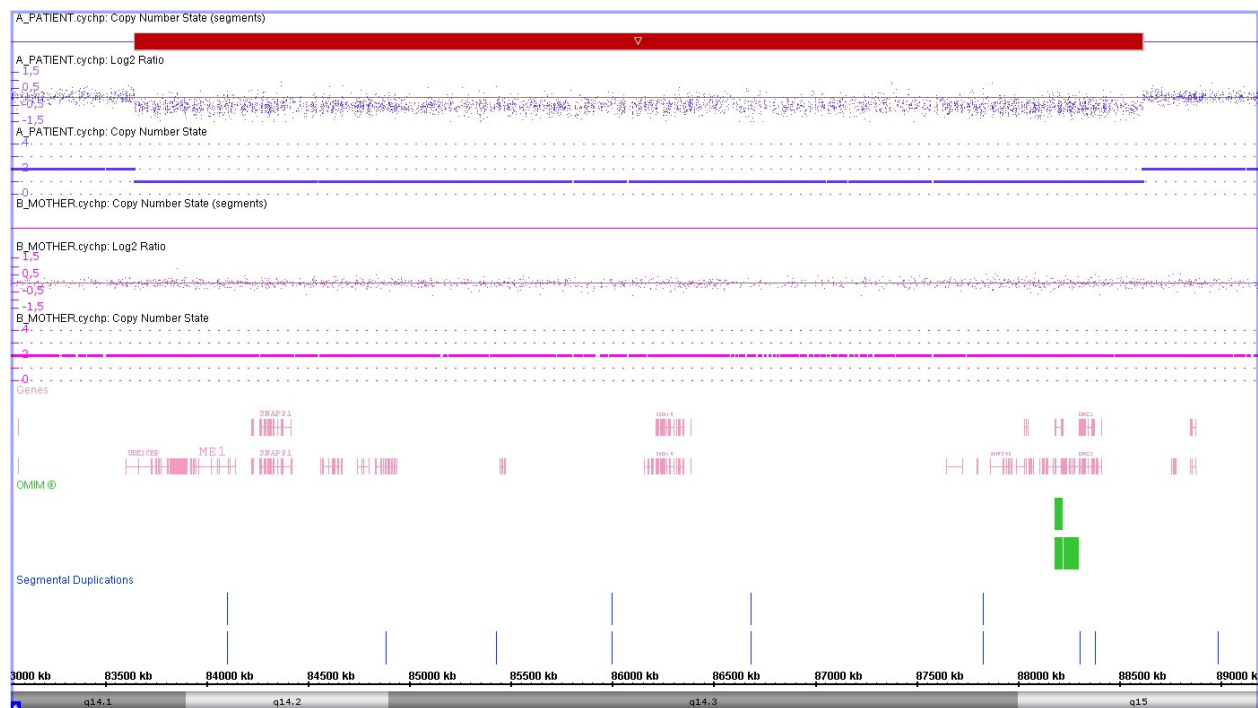


Figure 1. Microarray-based copy number analysis performed with the Affymetrix CytoScan High-Density array (patient) and the Affymetrix CytoScan 750K array (his mother) and visualized using the Affymetrix Chromosome Analysis Suite version 1.2.2. Image of the 4.96 Mb deletion at 6q14.1-q15 (chromosome 6: 83,648,997–88,613,065 bp; hg19) present in the patient (A) and absent in his mother (B). The father's DNA was not available for genetic analysis.

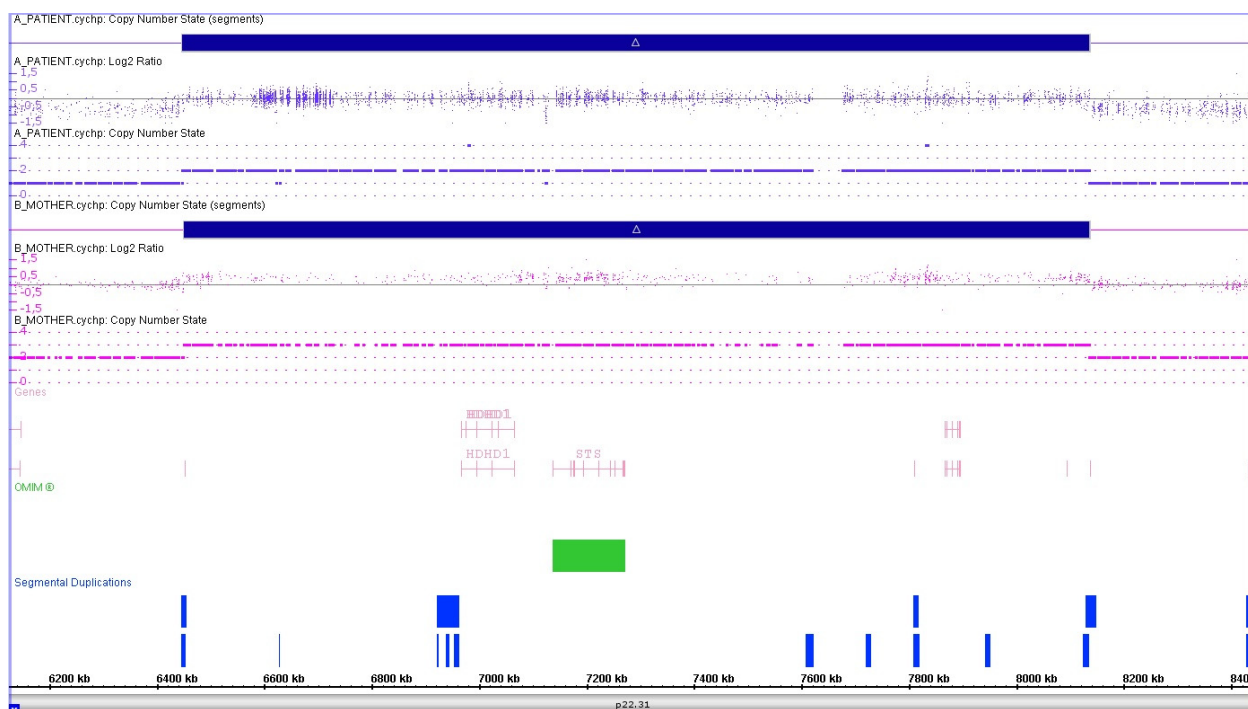


Figure 2. Microarray-based copy number analysis performed with the Affymetrix CytoScan High-Density array (patient) and the Affymetrix CytoScan 750K array (his mother) and visualized using the Affymetrix Chromosome Analysis Suite version 1.2.2. Image of the 1.69 Mb gain at Xp22.31 (chromosome X: 6,446,579–8,135,644 bp; hg19) present in both the patient (A) and his mother (B).

Clinodactyly of both fifth fingers. No pigmentary abnormalities were observed. Normal results were obtained in the following tests: Audiometry and auditory evoked potentials, brain Magnetic Resonance Imaging (MRI), dorsal/lumbar spine MRI (unless a doubtful segmentation in D10 which has been attributed to his scoliosis), and renal ultrasound. At the behavioral level, no sleeping or eating difficulties were noted. He presented enuresis and encopresis that remain to date.

At 3 years and 9 months, an extensive clinical interview was performed and he was diagnosed with pervasive developmental disorder, specifically AD, according to the Diagnostic, and Statistical Manual of Mental Disorders, Fourth Edition, Text Revision (DSM-IV-TR). In addition, the Childhood Autism Rating Scale (CARS [17]) was applied, achieving a score of 39, which placed him in the category of severe autism.

At 8 years, the patient underwent a comprehensive autism-focused diagnostic assessment. Results from the Autism Diagnostic Interview – Revised (ADI-R) were consistent with AD: Qualitative Abnormalities in Reciprocal Social Interaction (total score 27; cutoff = 10); Qualitative Abnormalities in Communication (total score 14; cutoff = 8); Restricted, Repetitive and Stereotyped Patterns of Behavior (total score 10; cutoff = 3); Abnormality of Development Evident at or before 36 months (total score 4; cutoff = 1).

At the same age, the Child Behavior Checklist (CBCL [18]) was administered. Results pointed to two main areas of clinical concern: lack of communication and hyperactivity. Finally, it was not possible to proceed with the neuropsychological assessment, since the patient refused to cooperate and showed no interest in the interaction with the evaluator. Nevertheless, clinical judgment led to conclude that his cognitive abilities and adaptive behavior were compatible with the diagnostic of severe intellectual disability.

From data collected at the above-mentioned different points of assessment, we can remark some patient's clinical and developmental characteristics. Early signs of developmental delay appeared around 4–6 months old because of hypotonia and both fine and gross motor deficits. He reached unsupported sitting before the first year and independent walking at 22 months.

The development of the prelinguistic communication showed an evident delay. At 1 year and 6 months, his use of gestures was limited to imitation and the use of the “goodbye”, although external elicitation was always necessary. The lack of pointing gesture was particularly evident, both in the protoimperative and protodeclarative forms. To date, he continues without being able to point and barely understands the meaning of this gesture in others. The development of nonverbal communication strategies

remained without improvement. Around 3 years, he did not use gestures or basic facial expressions and only very occasionally responded to his own name. He is still described as a very inexpressive child (except for the fact that frowns when he is angry). However, he uses some body gestures (mostly stereotypes) to help the expression of emotional states. Eye contact, although brief, is presumed to have improved from previous stages. Nevertheless, he avoids eye contact except with his mother.

Regarding language development, his first words occurred when he was 1-year-old. He began producing only a couple of words with referential meaning, but he did not show progress over the time. At 3 years, an evident verbal regression was observed, until a complete absence of expressive language. To date, he continues being nonverbal, with a very limited language understanding. In the last year, alternative/augmentative communication systems were introduced.

At the social area, he was a baby who did not show a clear interest neither in things from his near environment nor in interactive and circular games with social agents. He did not show use of attachment objects. As a remarkable social behavior, he only developed the social smile, a characteristic still present to date.

At the beginning of preschool age, he rejected to hold interactions with his peers. However, at the primary school years he started to show some interest in other children, although he still prefers to be with adults. His games are very simple and little structured. From primary education, he has required special educational support, both at and outside school.

In relation to behavior, he displays a clear hyperactive profile. He presents special difficulties with focused and sustained attention. He tends to show repetitive behaviors

and several motor stereotypes (such as turn on and turn off lights, open and close doors, jumps, hand flapping, claps, bizarre “goodbye” gestures, etc.). When he is very angry or under stress, he grabs his head with the hands and rubs or leans himself against a wall.

In the present patient, besides a diagnosis of AD, symptoms, and signs obtained through his clinical interview and psychopathological examination suggest a comorbid diagnosis of attention deficit and hyperactivity disorder (ADHD) and intellectual disability.

Craniofacial features at the age of 8 years are shown in Figure 3.

Molecular analysis

Microarray-based copy number analysis, performed with the CytoScan High-Density SNP array (Affymetrix), allowed the detection of two rare exonic CNVs in our patient: a heterozygous 4.96 Mb loss at 6q14.1-q15 (chromosome 6: 83,648,997–88,613,065 bp; hg19) including 31 genes (*UBE2CBP*, *DOPEY1*, *PGM3*, *RWDD2A*, *ME1*, *PRSS35*, *SNAP91*, *RIPPLY2*, *CYB5R4*, *MRAP2*, *KIAA1009*, *TBX18*, *NT5E*, *SNX14*, *SYNCRIP*, *SNHG5*, *SNORD50A*, *SNORD50B*, *HTR1E*, *CGA*, *ZNF292*, *GJB7*, *C6orf162*, *C6orf163*, *C6orf164*, *C6orf165*, *SLC35A1*, *RARS2*, *ORC3*, *AKIRIN2*, and *NCRNA00120*) (Fig. 1A) and a 1.69 Mb copy number gain at Xp22.31 (chromosome X: 6,446,579–8,135,644 bp; hg19) encompassing six genes (*VCX3A*, *HDHD1*, *STS*, *VCX*, *PNPLA4*, and *MIR651*) (Fig. 2A). A total of 4124 and 4408 markers with a median intermarker distance of 1.2 and 0.4 kb, respectively, cover the 6q14.1-q15 and Xp22.31 intervals, respectively. The genetic analysis of the patient's mother, performed with the Affymetrix CytoScan 750K SNP array, verified that she carries the Xp22.31 gain (Fig. 2B) but

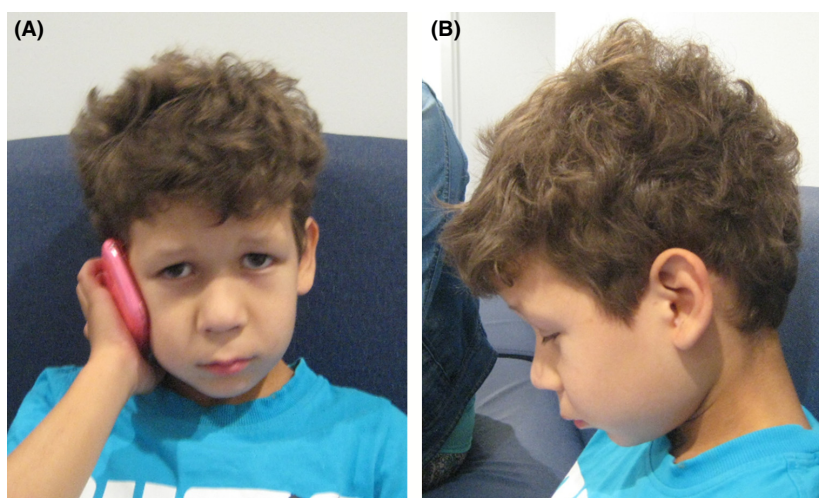


Figure 3. Craniofacial appearance of the patient at the age of 8 years. Note a squared craniofacial profile, a wide forehead, sparse eyebrows in the outer portion, antimongoloid palpebral slant, a long and prominent philtrum, micrognathia, and large ears.

not the 6q14.1-q15 microdeletion (Fig. 1B). The father's sample was not available for genetic analysis.

Discussion

The use of high-resolution chromosomal microarrays for CNV detection is favoring the identification of submicroscopic chromosomal abnormalities, undetectable by conventional cytogenetic techniques and with an approach that allows to study the whole genome in a single test [19–21]. Consequently, their application in the clinical setting has increased the diagnostic yield in the genetic evaluation of patients with neurodevelopmental and psychiatric disorders [22, 23]. However, the interpretation of the genetic findings is not always straightforward [24], being hampered by the detection of benign variants and/or variants of uncertain significance and/or by the coexistence of multiple genetic variants within a single genome. These two possibilities occur in our patient who, in addition to a deletion in the long arm of chromosome 6 (Fig. 1), has a maternally inherited variant of unclear significance at Xq22.31 (Fig. 2).

Figure 4 shows the submicroscopic interstitial deletions at 6q13-q16.1 reported in the literature with total or partial overlapping with the 6q14.1-q15 deletion identified in

our patient. These alterations have been detected by molecular cytogenetic techniques in patients with heterogeneous phenotypes, are rare variants, differ in size, and location, and encompass different genes [1–6] (Fig. 4), making the delineation of genotype-phenotype correlations a challenging task. However, Wentzel et al. [5] reported two patients with deletions at chromosome 6q14.1-q15, one of them almost identical in size, location, and gene content to that of our patient (Fig. 4A–B). These two reported patients have a common phenotype characterized by DD, motor delay, early-onset obesity, hernia, characteristic facial dysmorphism (rounded face with full cheeks, epicanthal folds, short palpebral fissures, bulbous nose, large ears), and syndactyly between toes II and III [5], features all shared by a previously published patient with an overlapping deletion in this region [25]. Additional features of patient 1 described by Wentzel et al. [5] include small and obese hands and feet, with fragile nails and ophthalmological, hearing and renal abnormalities as well as attention deficit and aggressive behavior. His patient 2 also presented additional clinical manifestations, including ophthalmologic abnormalities, mild pectus excavatum, early scoliosis improved with age, inverted nipples, a café-au-lait patch on the right side of his chest, ECG anomalies (mild right ventricular conduction delay)

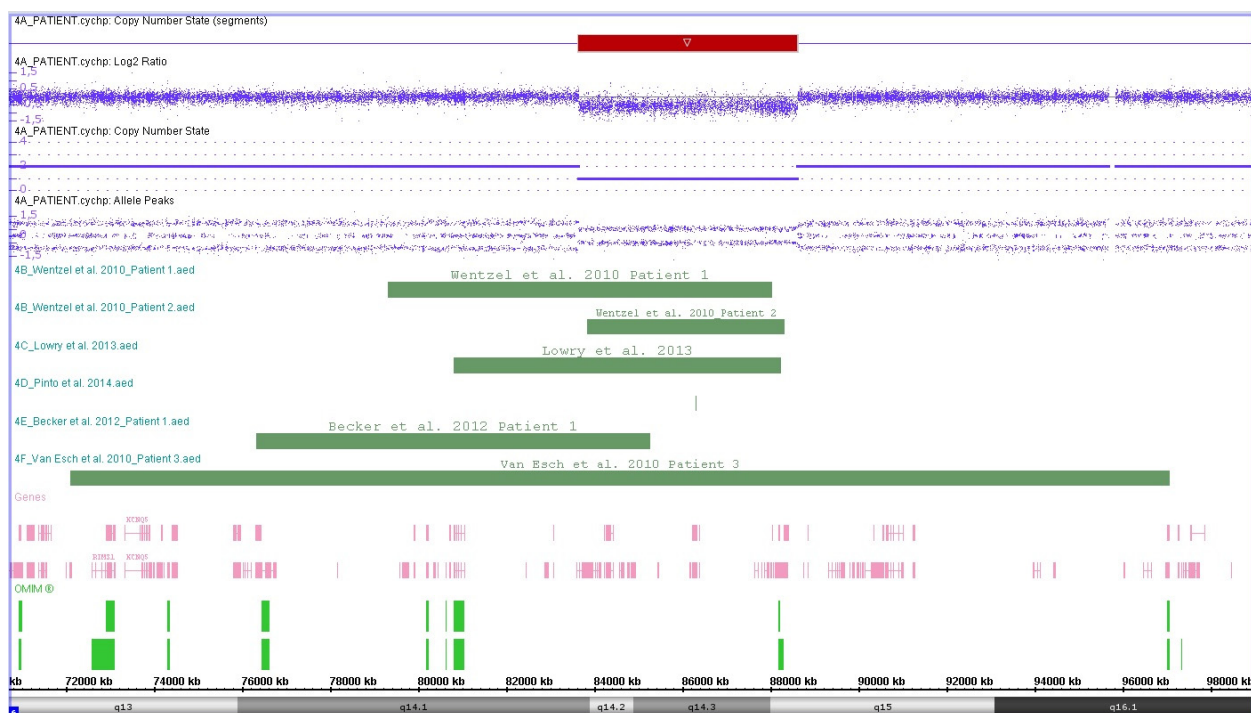


Figure 4. Schematic overview of the 6q14.1-q15 region showing the *RefSeq* and OMIM-morbidity genes and SNP array results in our patient and in previous reports with interstitial submicroscopic 6q14.1-q15 deletions identified by molecular techniques [1–5]. The UCSC Genome LiftOver Tool was used for converting genome coordinates between hg18 and hg19 assemblies, where necessary. Longer interstitial 6q deletions described in the literature and detected by conventional cytogenetics are not included in this scheme [reviewed by Refs. 42, 43].

and, regarding his behavior, he was hyperactive and had anomalous seeking food behaviors [5]. Our patient has a deletion similar in size and location to that of this patient 2, which is almost entirely included into patient 1's deletion (Fig. 4A–B) [5]; however, despite the similarities in their genotypes, not only phenotypic resemblances but also significant differences between these patients were noted. The features shared by the above-mentioned patients and the one presented here include: DD, motor delay, hypotonia, digital abnormalities, and some (i.e., large ears; bulbous nose) but not all the facial dysmorphic characteristics. Our patient, however, does not have early-onset obesity (strikingly, he is thin rather than obese) or hernia or any of the congenital abnormalities reported by Wentzel et al. [5], such as cardiac, ophthalmologic, hearing, renal, or skeletal defects, with the sole exception of scoliosis. Finally, all these three patients have behavior problems, although some differences in this regard are also striking: attention deficit and aggressive behavior in patient 1, hyperactivity and obsessive seeking food behaviors in patient 2 [5] and AD and ADHD (but not aggressiveness or feeding problems) in our patient. It seems that interstitial deletions at 6q14.1-q15 might be associated with very different phenotypes, as it has been previously suggested by Lowry et al. [2]. These authors found that his patient, despite having a very similar deletion to patient 1 described by Wentzel et al. [5], only shared some features (DD, hypotonia, and anomalous feeding behavior), but had a completely different facial dysmorphism and, as our patient, was thin rather than obese [2]. Recently, Pinto et al. [3] described a male patient with A, severe ID, absence of language, one seizure event in his life, macrocephaly, long and narrow hands and feet and 2 café-au-lait spots and a de novo 23 kb 6q14.3 microdeletion encompassing two genes, *SYNCRIP* and *SNX14*, both deleted in our patient (Fig. 4D). Becker et al. [1] have also reported two patients with 6q chromosomal alterations, one with a de novo deletion of 8.9 Mb in the 6q14.1-q14.3 region partially overlapping with that of our patient. His phenotype was characterized by neonatal jaundice, DD, cardiac malformations, and dysmorphic features (Fig. 2E). Finally, one of the four patients described by Van Esch et al. [4] with 6q13-q14 deletions has a de novo 25 Mb deletion, which includes our patient's CNV. The phenotype was characterized by DD, mild dysmorphism, umbilical hernia, hypotonia, small kidneys and skeletal, ophthalmologic and hearing abnormalities, as well as recurrent respiratory infections (Fig. 4F). It seems, therefore, that interstitial deletions at the proximal 6q region are associated with heterogeneous phenotypes and these differences might be due to multiple reasons: (1) For those deletions more similar in size, location, and gene content, such as the one in our patient and in patients described by Wentzel et al. [5] and

Lowry et al. [2] (Fig. 4A–C), one could speculate with the existence of recessive mutations in the nondeleted allele and/or the presence of additional modifying factors elsewhere in the genome, as could be the case of the Xp22.31 gain in our patient and the 1p31.1 duplication in patient 2 reported by Wentzel et al. [5], as well as environmental and/or epigenetic modifiers. (2) In the case of the other aforementioned CNVs [1, 3, 4] (Fig. 4D–F), difference in size, location, breakpoints and, in consequence, gene content might account for this phenotypic heterogeneity.

The 6q region deleted in our patient encompasses 31 genes in total, including *SLC35A1* (Solute carrier family 35 (CMP-sialic acid transporter), member 1; Online Mendelian Inheritance in Man (OMIM) 605634) and *RARS2* (Arginyl-tRNA synthetase 2; OMIM 611524) as morbidity genes listed in the OMIM database and are cause of congenital disorder of glycosylation type Iif (OMIM 603585) and pontocerebellar hypoplasia type 6 (OMIM 611523), respectively. Candidate genes for our patient's phenotype can potentially include: *PGM3* (phosphoglucomutase 3), *PRSS35* (protease, serine, 35), *SNAP91* (synaptosomal-associated protein, 91kDa), *RIPPLY2* (rippy transcriptional repressor 2), *MRAP2* (melanocortin 2 receptor accessory protein 2), *SYNCRIP* (synaptotagmin binding, cytoplasmic RNA interacting protein), *SNX14* (sorting nexin 14), and *HTR1E* (5-hydroxytryptamine (serotonin) receptor 1E, G protein-coupled). Thus, Zhang et al. [26] have recently detected, in two unrelated families, recessive mutations in the gene *PGM3* that segregate with a phenotype characterized by severe atopy, immune deficiency, autoimmunity, hypomyelination, and ID. A genome-wide association study has suggested an association between psychotic features (mood-incongruent psychotic features) of bipolar disorder and common polymorphisms in several genes expressed in the nervous system, including a SNP located at 6q14.2 within the gene complex *PRSS35-SNAP91*, although did not reach statistical significance [27]. It has also been suggested that *PRSS35* could be involved in craniofacial abnormalities, particularly in cleft lip/palate [28]. Also interestingly, McInerney-Leo et al. [29] have recently identified compound heterozygous mutations in *RIPPLY2* segregating in a family with vertebral segmentation defects, further supporting previous evidence for a role in somite segmentation and the establishment of rostrocaudal patterning of somites during mouse early development [30–32] and providing a plausible candidate gene for the skeletal defects seen in patients with 6q14.1-q15 deletions, as the one reported here. Although, as previously mentioned, patient described by Lowry et al. [2] and our patient are thin rather than obese, early-onset obesity has been reported in several patients with deletions at 6q14.1-q15 [5]. One of the genes included in these deletions, *MRAP2*, has been

linked to obesity in mammals and zebrafish [33–35], so one could hypothesize that this gene might also be involved in the obesity seen in these patients, for example, unmasking recessive loss-of-function mutations in the nondeleted allele. Although additional evidence is needed to definitively consider *SYNCRIP* causal for neurodevelopmental disorders, it is important to note that a de novo loss-of function mutation has been reported in this gene in a patient with severe nonsyndromic ID [36] and, as previously discussed, Pinto et al. [3] have recently found a de novo microdeletion affecting *SYNCRIP* and *SNX14* in a patient with a phenotype mainly characterized by A, severe ID, and absence of language, similar to our patient. Finally, several genetic approaches (linkage, family-based, candidate gene, and genome-wide association studies) have suggested a potential role for *HTR1E* in ADHD [37–39] and suicidal behavior [40] and epigenetic studies have provided evidence of differential methylation of the promoter of *HTR1E* in patients with first-episode schizophrenia versus controls [41].

Duplications at the subtelomeric Xq22.31 region, where deletions or mutations affecting the *STS* gene (Steroid Sulfatase; OMIM 300747) are involved in X-linked ichthyosis (OMIM 308100), vary in size, location, and gene content, and have been considered as either a cause or risk factor for DD/ID or a benign variant, still existing a controversy regarding its clinical significance [6–15]. Thus, Li et al. [10] identified 29 individuals of a total of 7993 patients (0.37%) with DD, DI, A, dysmorphism, and/or MCA with subtelomeric Xp22.31 copy number gains ranging in size between 149 kb and 1.74 Mb. Nevertheless, they also found Xp22.31 alterations in control population and although the frequency was lower (0.15%), their findings questioned the pathogenicity of these CNVs. Subsequently and in larger series of samples, Liu et al. [11] also studied and compared the frequencies of the Xp22.31 copy number gains between patients ($n = 20,095$) and controls ($n = 5088$) and no statistically significant differences were found, neither in the overall prevalence nor when the data were analyzed by gender. Furthermore, they found that these alterations were mostly inherited from a healthy parent, further complicating the clinical interpretation. Finally, Furrow et al. [6] argued that these duplications were benign; they detected duplications of the *STS* region in 72 male patients and segregation analysis in 40 of them revealed that each patient had inherited the CNV from a phenotypically normal mother. Furthermore, 10 of the 72 patients (14%) had an additional CNV that was believed to be causative of their phenotypes. Nevertheless, Faletta et al. [9] found that no Xp22.31 duplications were detected in a total of 2055 control individuals and concluded that this finding, along with the description of a new patient with a de

novo Xp22.31 duplication, would support the pathogenicity of this CNV leading to a phenotype of ID and minor facial dysmorphism without major anomalies. Recently, Esplin et al. [8] described nine patients with duplications of Xp22.31 that seem to contribute to a common phenotype mainly characterized by DD, talipes abnormalities, seizures, feeding difficulties, and a variable facial dysmorphism. Concerning the phenotype, Liu et al. [11] obtained detailed clinical information of 14 of their patients, who mainly presented DD and behavioral and social interaction problems, including stereotypic features such as hand flapping and avoidance of eye contact, features all presented in our patient.

There are different plausible explanations for the incomplete penetrance and the phenotypic heterogeneity of these X-CNVs, including the following: (1) Difference in size, location and genomic content of the copy number gains [8, 10, 11]. (2) Difference in their population frequencies, as it has been suggested by Li et al. [10] and Liu et al. [11]. (3) Unnoticed phenotype in controls and/or carrier parents if it is presented as a milder or subclinical phenotype [11] or if improves with age. (4) Skewed X-inactivation, although discrepancies between authors have been reported [10, 11]. (5) That the Xp22.31 copy number gain is not the cause but a risk factor that triggers the phenotype if additional factors are present. These modifiers could be environmental, genetic (supporting the multiple-hit hypothesis) and/or epigenetic factors. In this regard, Liu et al. [11] found that at least 17.2% of the patients with the recurrent duplication carried additional CNVs in their genomes and suggested that these could contribute to their phenotypic manifestations. This is also the case of our patient who, in addition to the maternally inherited Xp22.31 gain of unclear clinical significance, carries the above-mentioned 6q14.1-q15 microdeletion.

The breakpoints of the Xp22.31 copy number gain in our patient are flanked by segmental duplications (Fig. 2) so, as it has been proposed [11], nonallelic homologous recombination (NAHR) is likely the underlying mechanism.

In conclusion, we have described here a patient who harbors a 6q14.1-q15 microdeletion and presents severe AD, lack of oral language and dysmorphic features. The use of genome-wide high-resolution SNP arrays for copy number analysis has been proven to be an extremely valuable approach in the identification of genetic causes of neurodevelopmental disorders. However, discrimination between benign and pathogenic variants and the establishment of genotype-phenotype correlations are not always straightforward tasks. Thus, our report may represent an example to illustrate the difficulty in interpreting genetic data, especially when these variants present phenotypic heterogeneity and/or incomplete penetrance and/or when

multiple variants, associated with overlapping phenotypes, coexist in a single genome. In addition, we emphasize the need to report detailed clinical descriptions to facilitate this interpretation and to aid to provide appropriate family genetic counseling and patient management.

Acknowledgments

We are grateful to the patient and his parents for their collaboration. Genotyping services were provided by the “Centro Nacional de Genotipado- Plataforma de Recursos Biomoleculares y Bioinformaticos – Instituto de Salud Carlos III (CeGen-PRB2-ISCIII)”. The contribution of Maria Jose Jove Foundation is also acknowledged with appreciation.

Conflict of Interest

None declared.

References

1. Becker, K., N. Di Donato, M. Holder-Espinasse, J. Andrieux, J. M. Cuisset, L. Vallee, et al. 2012. De novo microdeletions of chromosome 6q14.1-q14.3 and 6q12.1-q14.1 in two patients with intellectual disability – further delineation of the 6q14 microdeletion syndrome and review of the literature. *Eur. J. Med. Genet.* 55:490–497.
2. Lowry, R. B., J. E. Chernos, M. S. Connelly, and J. P. Wyse. 2013. Interstitial deletions at 6q14.1q15 associated with developmental delay and a marfanoid phenotype. *Mol. Syndromol.* 4:280–284.
3. Pinto, D., E. Delaby, D. Merico, M. Barbosa, A. Merikangas, L. Klei, et al. 2014. Convergence of genes and cellular pathways dysregulated in autism spectrum disorders. *Am. J. Hum. Genet.* 94:677–694.
4. Van Esch, H., E. M. Rosser, S. Janssens, I. Van Ingelghem, B. Loeys, and B. Menten. 2010. Developmental delay and connective tissue disorder in four patients sharing a common microdeletion at 6q13-14. *J. Med. Genet.* 47:717–720.
5. Wentzel, C., S. A. Lynch, E. L. Stattin, F. H. Sharkey, G. Anneren, and A. C. Thureson. 2010. Interstitial deletions at 6q14.1-q15 associated with obesity, developmental delay and a distinct clinical phenotype. *Mol. Syndromol.* 1:75–81.
6. Furrow, A., A. Theisen, L. Velsher, E. V. Bawle, S. Sastry, N. J. Mendelsohn, et al. 2011. Duplication of the STS region in males is a benign copy-number variant. *Am. J. Med. Genet. A* 155A:1972–1975.
7. Baldwin, E. L., J. Y. Lee, D. M. Blake, B. P. Bunke, C. R. Alexander, A. L. Kogan, et al. 2008. Enhanced detection of clinically relevant genomic imbalances using a targeted plus whole genome oligonucleotide microarray. *Genet. Med.* 10:415–429.
8. Esplin, E. D., B. Li, A. Slavotinek, A. Novelli, A. Battaglia, R. Clark, et al. 2014. Nine patients with Xp22.31 microduplication, cognitive deficits, seizures, and talipes anomalies. *Am. J. Med. Genet. A* 164:2097–2103.
9. Faletta, F., A. P. D’Adamo, M. Santa Rocca, M. Carrozzi, M. D. Perrone, V. Pecile, et al. 2012. Does the 1.5 Mb microduplication in chromosome band Xp22.31 have a pathogenetic role? New contribution and a review of the literature. *Am. J. Med. Genet. A* 158A:461–464.
10. Li, F., Y. Shen, U. Kohler, F. H. Sharkey, D. Menon, L. Coulleaux, et al. 2010. Interstitial microduplication of Xp22.31: causative of intellectual disability or benign copy number variant? *Eur. J. Med. Genet.* 53:93–99.
11. Liu, P., A. Erez, S. C. Nagamani, W. Bi, C. M. Carvalho, A. D. Simmons, et al. 2011. Copy number gain at Xp22.31 includes complex duplication rearrangements and recurrent triplications. *Hum. Mol. Genet.* 20: 1975–1988.
12. Mencarelli, M. A., E. Katzaki, F. T. Papa, K. Sampieri, R. Caselli, V. Uliana, et al. 2008. Private inherited microdeletion/microduplications: implications in clinical practice. *Eur. J. Med. Genet.* 51:409–416.
13. Shaffer, L. G., B. A. Bejjani, B. Torchia, S. Kirkpatrick, J. Coppinger, and B. C. Ballif. 2007. The identification of microdeletion syndromes and other chromosome abnormalities: cytogenetic methods of the past, new technologies for the future. *Am. J. Med. Genet. C Semin. Med. Genet.* 145C:335–345.
14. Shaffer, L. G., C. D. Kashork, R. Saleki, E. Rorem, K. Sundin, B. C. Ballif, et al. 2006. Targeted genomic microarray analysis for identification of chromosome abnormalities in 1500 consecutive clinical cases. *J. Pediatr.* 149:98–102.
15. Shaw-Smith, C., R. Redon, L. Rickman, M. Rio, L. Willatt, H. Fiegler, et al. 2004. Microarray based comparative genomic hybridisation (array-CGH) detects submicroscopic chromosomal deletions and duplications in patients with learning disability/mental retardation and dysmorphic features. *J. Med. Genet.* 41:241–248.
16. Girirajan, S., J. A. Rosenfeld, G. M. Cooper, F. Antonacci, P. Siswara, A. Itsara, et al. 2010. A recurrent 16p12.1 microdeletion supports a two-hit model for severe developmental delay. *Nat. Genet.* 42:203–209.
17. Schopler, E., J. Reichler, and B. Renner. 1998. The Childhood Autism Rating Scale (CARS). Western Psychological Services, Los Angeles, CA.
18. Achenbach, T.M. 1991. Manual for the Child Behavior Checklist / 4–18 and 1991 profile. Department of Psychiatry, University of Vermont, Burlington.
19. Ahn, J. W., S. Bint, A. Bergbaum, K. Mann, R. P. Hall, and C. M. Ogilvie. 2013. Array CGH as a first line diagnostic test in place of karyotyping for postnatal referrals – results from four years’ clinical application for over 8,700 patients. *Mol. Cytogenet.* 6:16.

20. Battaglia, A., V. Doccini, L. Bernardini, A. Novelli, S. Loddo, A. Capalbo, et al. 2013. Confirmation of chromosomal microarray as a first-tier clinical diagnostic test for individuals with developmental delay, intellectual disability, autism spectrum disorders and dysmorphic features. *Eur. J. Paediatr. Neurol.* 17:589–599.
21. Miller, D. T., M. P. Adam, S. Aradhya, L. G. Biesecker, A. R. Brothman, N. P. Carter, et al. 2010. Consensus statement: chromosomal microarray is a first-tier clinical diagnostic test for individuals with developmental disabilities or congenital anomalies. *Am. J. Hum. Genet.* 86:749–764.
22. Utine, G. E., G. Haliloglu, B. Volkan-Salanci, A. Cetinkaya, P. O. Kiper, Y. Alanay, et al. 2014. Etiological yield of SNP microarrays in idiopathic intellectual disability. *Eur. J. Paediatr. Neurol.* 18:327–337.
23. Vulto-van Silfhout, A. T., J. Y. Hehir-Kwa, B. W. van Bon, J. H. Schuurs-Hoeijmakers, S. Meader, C. J. Hellebrekers, et al. 2013. Clinical significance of de novo and inherited copy-number variation. *Hum. Mutat.* 34:1679–1687.
24. Hehir-Kwa, J. Y., R. Pfundt, J. A. Veltman, and N. de Leeuw. 2013. Pathogenic or not? Assessing the clinical relevance of copy number variants. *Clin. Genet.* 84:415–421.
25. Turleau, C., G. Demay, M. O. Cabanis, G. Lenoir, and J. de Grouchy. 1988. 6q1 monosomy: a distinctive syndrome. *Clin. Genet.* 34:38–42.
26. Zhang, Y., X. Yu, M. Ichikawa, J. J. Lyons, S. Datta, I. T. Lamborn, et al. 2014. Autosomal recessive phosphoglucomutase 3 (PGM3) mutations link glycosylation defects to atopy, immune deficiency, autoimmunity, and neurocognitive impairment. *J. Allergy Clin. Immunol.* 133:1400–1409, 1409.e1–5.
27. Goes, F. S., M. L. Hamshere, F. Seifuddin, M. Pirooznia, P. Belmonte-Mahon, R. Breuer, et al. 2012. Genome-wide association of mood-incongruent psychotic bipolar disorder. *Transl. Psychiatr.* 2:e180.
28. Letra, A., R. Menezes, R. F. Fonseca, M. Govil, T. McHenry, M. J. Murphy, et al. 2010. Novel cleft susceptibility genes in chromosome 6q. *J. Dent. Res.* 89:927–932.
29. McInerney-Leo, A. M., D. B. Sparrow, J. E. Harris, B. B. Gardiner, M. S. Marshall, V. C. O'Reilly, et al. 2014. Compound heterozygous mutations in RIPPLY2 associated with vertebral segmentation defects. *Hum. Mol. Genet.* pii: dd534.
30. Biris, K. K., W. C. Dunty, and T. P. Yamaguchi. 2007. Mouse Ripply2 is downstream of Wnt3a and is dynamically expressed during somitogenesis. *Dev. Dyn.* 236:3167–3172.
31. Chan, T., A. Kondow, A. Hosoya, K. Hitachi, A. Yukita, K. Okabayashi, et al. 2007. Ripply2 is essential for precise somite formation during mouse early development. *FEBS Lett.* 581:2691–2696.
32. Morimoto, M., N. Sasaki, M. Oginuma, M. Kiso, K. Igarashi, K. Aizaki, et al. 2007. The negative regulation of Mesp2 by mouse Ripply2 is required to establish the rostro-caudal patterning within a somite. *Development* 134:1561–1569.
33. Asai, M., S. Ramachandrappa, M. Joachim, Y. Shen, R. Zhang, N. Nuthalapati, et al. 2013. Loss of function of the melanocortin 2 receptor accessory protein 2 is associated with mammalian obesity. *Science* 341:275–278.
34. Liu, T., J. K. Elmquist, and K. W. Williams. 2013. Mrap2: an accessory protein linked to obesity. *Cell Metab.* 18:309–311.
35. Sebag, J. A., C. Zhang, P. M. Hinkle, A. M. Bradshaw, and R. D. Cone. 2013. Developmental control of the melanocortin-4 receptor by MRAP2 proteins in zebrafish. *Science* 341:278–281.
36. Rauch, A., D. Wieczorek, E. Graf, T. Wieland, S. Ende, T. Schwarzmayr, et al. 2012. Range of genetic mutations associated with severe non-syndromic sporadic intellectual disability: an exome sequencing study. *Lancet* 380:1674–1682.
37. Amin, N., Y. S. Aulchenko, M. C. Dekker, R. F. Ferdinand, A. van Spreken, A. H. Temmink, et al. 2009. Suggestive linkage of ADHD to chromosome 18q22 in a young genetically isolated Dutch population. *Eur. J. Hum. Genet.* 17:958–966.
38. Lasky-Su, J., B. M. Neale, B. Franke, R. J. Anney, K. Zhou, J. B. Maller, et al. 2008. Genome-wide association scan of quantitative traits for attention deficit hyperactivity disorder identifies novel associations and confirms candidate gene associations. *Am. J. Med. Genet. B Neuropsychiatr. Genet.* 147B:1345–1354.
39. Oades, R. D., J. Lasky-Su, H. Christiansen, S. V. Faraone, E. J. Sonuga-Barke, T. Banaschewski, et al. 2008. The influence of serotonin- and other genes on impulsive behavioral aggression and cognitive impulsivity in children with attention-deficit/hyperactivity disorder (ADHD): findings from a family-based association test (FBAT) analysis. *Behav. Brain Funct.* 4:48.
40. Baca-Garcia, E., C. Vaquero-Lorenzo, M. M. Perez-Rodriguez, M. Gratacos, M. Bayes, R. Santiago-Mozos, et al. 2010. Nucleotide variation in central nervous system genes among male suicide attempters. *Am. J. Med. Genet. B Neuropsychiatr. Genet.* 153B:208–213.
41. Nishioka, M., M. Bundo, S. Koike, R. Takizawa, C. Kakiuchi, T. Araki, et al. 2013. Comprehensive DNA methylation analysis of peripheral blood cells derived from patients with first-episode schizophrenia. *J. Hum. Genet.* 58:91–97.
42. Hopkin, R. J., E. Schorry, M. Bofinger, A. Milatovich, H. J. Stern, C. Jayne, et al. 1997. New insights into the phenotypes of 6q deletions. *Am. J. Med. Genet.* 70:377–386.
43. Kumar, R., D. Riordan, A. J. Dawson, and A. E. Chudley. 1997. Proximal interstitial 6q deletion: a recognizable syndrome. *Am. J. Med. Genet.* 71:353–356.